

## From Our Office to Yours...

Implant dentistry has steadily evolved since Bränemark first applied orthopedic principles to endosseous dental implants.

In this issue of *The PerioDontaLetter*, we review the history of implants and current new technologies which have brought us from two-stage implants with lengthy healing times to the immediate placement of implants with optimum function and cosmetics under certain favorable circumstances.

As these new procedures become increasingly well-documented, we may be able to provide more immediate placement, immediate loading and immediate function of implants. As a result, your patients may enjoy shortened treatment times, less invasive procedures and the elimination of the need for interim prostheses.

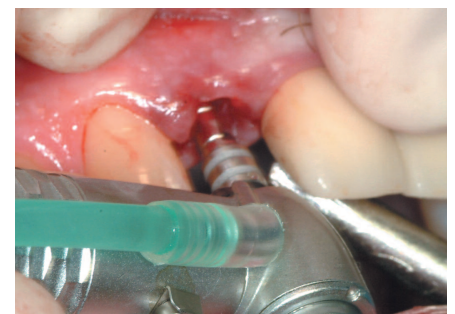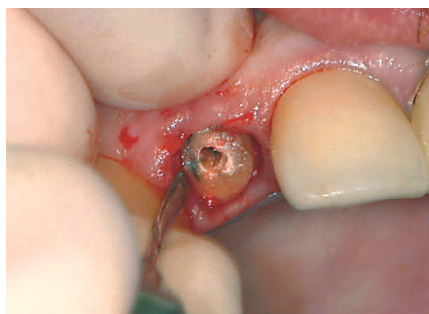
As always, we will continue to work with you to select the most appropriate method for each individual situation and patient. We look forward to your comments and suggestions and our continuing teamwork with your office to increase your patients' satisfaction with their implant treatment.

## Immediate Placement of Single Tooth Implants

The first patients receiving Bränemark implants were completely edentulous and received multiple (5-6) implants placed in the anterior mandible between the mental foramina, then later in the maxillary anterior region. All of these implants were the "two-stage" variety which classically required three to six months to complete the bone

fusion process named osseointegration. Then a second surgical procedure to expose the implant head for abutment connection and restoration was performed.

Although there were limitations imposed by Bränemark's system, including the design and cosmetics of the prostheses they supported, for many "dental cripples" the return of adequate function was nothing short



*Figure 1. A fractured lateral incisor was removed atraumatically using a flapless technique. Figure 2. The implant osteotomy was extended beyond the apex of the socket for initial implant stability. (See Figures 3 and 4.)*

of a miracle which significantly improved their quality of life.

As a means of treating areas of bone with less than adequate density and volume, alternative implant designs and geometry and the use of osteotomes, sinus augmentation and onlay grafts were developed to increase the predictability and clinical success of dental implants.

## The Single Tooth Implant

Beginning in the mid-90's, single tooth implants and reduction in treatment time became a primary goal for implant clinicians. Patients were dissatisfied with merely achieving a stable implant in alveolar bone and demanded functional and cosmetically-acceptable tooth replacements. As a result, the single tooth implant has become the treatment of choice AND the standard of care in many tooth replacement situations.

Daunting clinical obstacles were overcome, in particular the reproduction of lost alveolar bone and the overlying soft tissue which almost always accompanies tooth extraction. However, because attempts to regain lost tissues often subject the patient to multiple surgical procedures, which are often unpredictable in producing the desired clinical results, preservation of tissue became a primary objective. Placing an implant immediately into a fresh extraction site provided a treatment method with the potential of reducing the amount of invasive surgical care, minimizing treatment time, and providing the best opportunity for preservation of a normal periodontal tissue complex, especially in the interdental papilla.

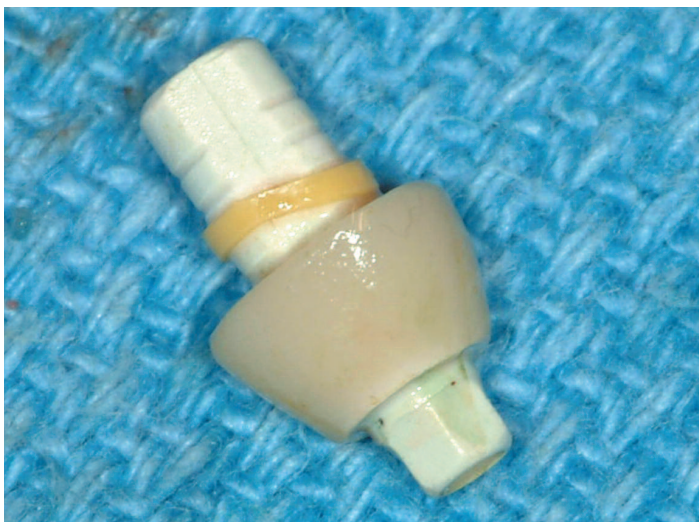
Several pivotal questions became apparent: Will an implant osseointegrate if portions of the implant surface are not in intimate contact with the bony socket walls? Can a provisional restoration be placed immediately on an implant to enhance esthetics during

healing? Can provisional restorations be placed on immediate implants and also into immediate, occlusal (loaded) function?

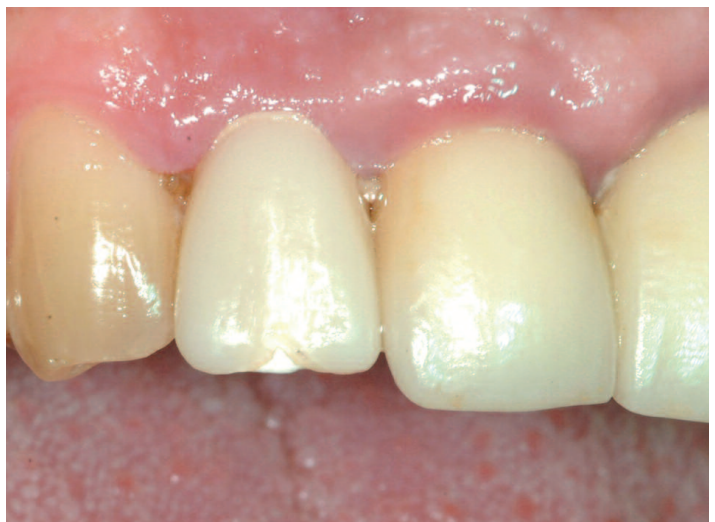Answers to these questions are still “a work in progress.” It is important to be mindful of the objectives -- maximizing successful function and esthetics while minimizing invasive surgical procedures in the face of public demand for single tooth implants with optimum results.

Palantonio et al addressed the issue of bone augmentation within a socket with adjoining immediately-placed implants. Their study showed similar osseointegration without bone grafts or membranes if the microgap between implant and socket wall was 2mm or less, and the flaps were closed over the implant.

It is recommended that immediate implants be placed slightly lingual to the original socket so as not to engage the labial plate. By not following the exact confines of the socket shape and placing the

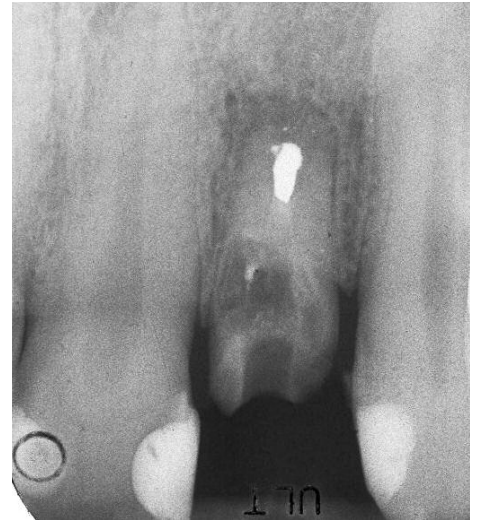
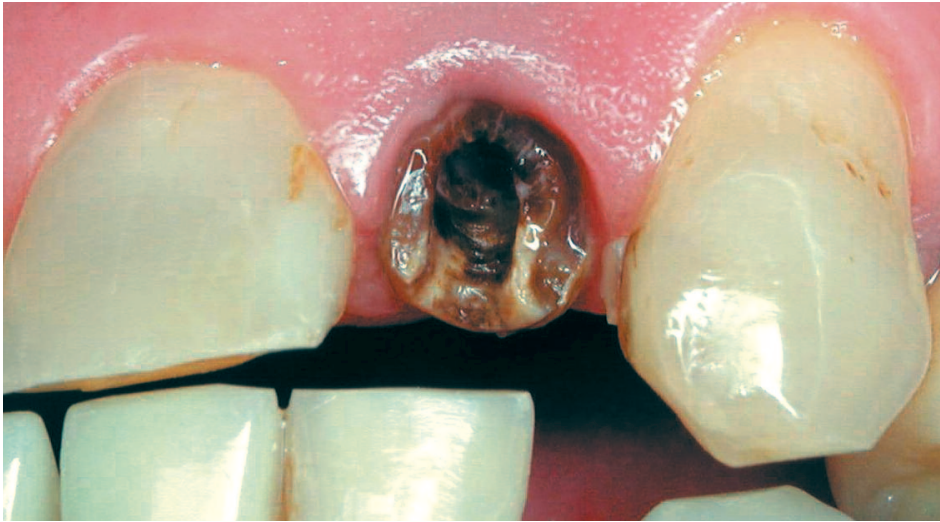
*Figure 3. Following implant placement, a custom healing abutment was fabricated to shape the gingival architecture.*



*Figure 4. The temporary healing abutment can be used for placement of an immediate temporary fixed restoration or reduced for the placement of a temporary partial.*





*Figures 5 and 6. The upper lateral incisor was decayed and fractured subgingivally.*

implant slightly lingual, long-term stability of the labial plate seems to be maintained.

In both studies, the implants were extended apically and/or laterally to the anatomic socket apex to gain favorable initial stabilization. Using this “native” bone when available apically ensures initial implant stability. Elimination of any micromovement has long been considered a basic prin-

ciple of implant success. This is of paramount importance in the design of the interim provisional restoration.

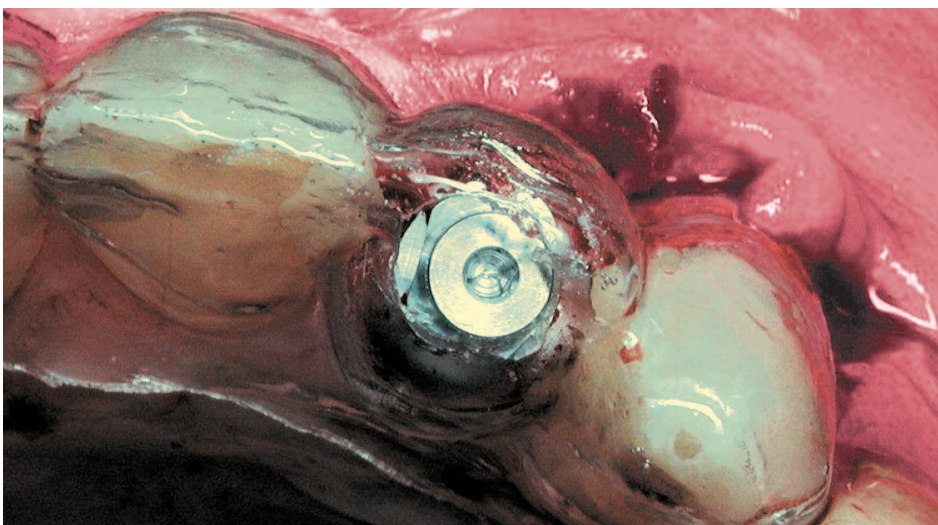
### **Immediate Loading of Implants**

Although somewhat controversial, some clinicians are advocating immediate loading of implants. This

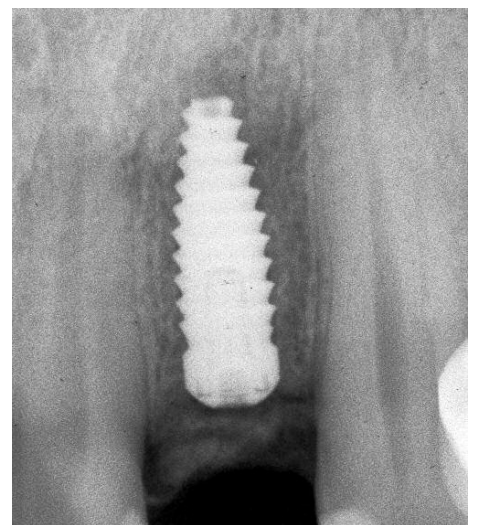
involves placing a temporary crown on the implant at the time of implant surgery.

When treatment planning a patient for immediate loading, one must first consider patient-related and environmental factors.

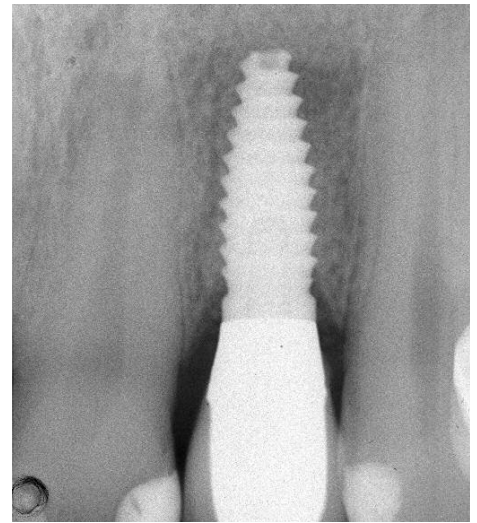
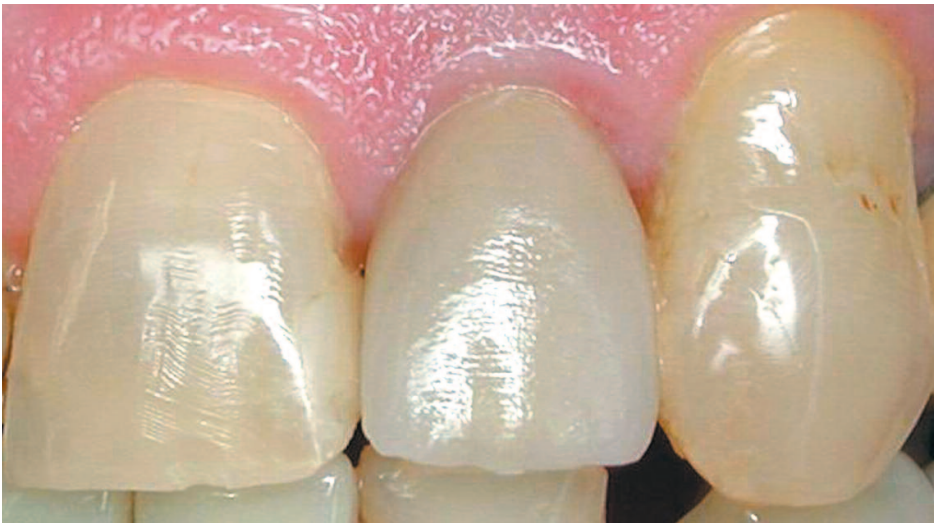- The healing potential of the patient is a critical issue.
- Systemic conditions including diabetes, compromised immunologi-



*Figure 7. The root was removed and, using a guide stent, the implant was placed into and beyond the socket for initial stability.*



*Figure 8. The radiograph confirms the implant has osseointegrated with the socket bone.*



*Figures 9 and 10. The clinical photograph and the radiograph confirm the appearance of the final restoration of the implant.*

cal status and life stresses do not favor immediate loading.

- Smoking and the presence of extensive periodontal disease are also contraindications to immediate loading.

- The character and quality of bone in the implant site may dictate a more conventional approach.

- Provisional prostheses which cannot be protected from overloading during function or from para-functional habits such as bruxism, are best treated in a more traditional manner.

- Large sockets in maxillary and mandibular molar regions which have the potential for defining less than ideal implant positioning favor bone regeneration and delayed implant placement.

In summary, it is important to remember that the concepts for immediate placement, restoration and loading are completely dependent upon the availability of alveolar bone.

The long-term success of any dental implant is predicated on the quality and quantity of the bone into which it is being placed. If the bone is wide, tall and dense, chances for a successful implant, which will last a lifetime, are very good indeed. If the bone is deficient in any one of these dimensions, bone modification or supplementation may be required prior to implant placement. In patients presenting with inadequate bone, it is ill-advised to attempt any type of immediate implant procedure.

### **One Miracle at a Time**

Dennis Tarnow, a leader in implant research and development, has said: **“The fact that we can replace a tooth with an implant is a miracle, and that we can grow bone which has been destroyed due to disease or atrophy is a miracle. Let’s only try to perform one miracle at a time.”**

What is most important is that implants be placed in the most favorable position for optimal function and cosmetics. It is here that we need the restoring doctor’s assistance in determining this position. This is where a pre-surgical diagnostic waxup and surgical guide showing the implant position in three planes -- buccal-lingual, mesial-distal and apical-coronal -- is critical.

This is our philosophy in treating your patients because we want the best long-term results possible.

We strive to make sure the bone is adequate and healthy prior to implant placement, and that the implant has had sufficient time to fully integrate prior to restoring it with a prosthetic tooth replacement.

Allowing sufficient time for proper healing or regeneration of bone and ensuring that the implants placed will last a lifetime is a small price to pay for a miracle.

