

## *From Our Office to Yours...*

*The use of provisional restorations in implant therapy is an important clinical step and should be carefully planned, prior to the surgical phase.*

*Well-conceived provisional restorations protect the surgical site from occlusal forces during the healing process, and can be used to shape the soft tissue during the maturation phase. This is particularly helpful in the management of the esthetic zone. Indeed, the provisional restoration provides both the prototype and "blueprint" for the final prosthesis.*

*In this current issue of **The PerioDontaLetter**, we review the importance of the provisional restoration during implant therapy.*

*As always, we welcome your questions and suggestions.*

## **The Provisional Restoration**

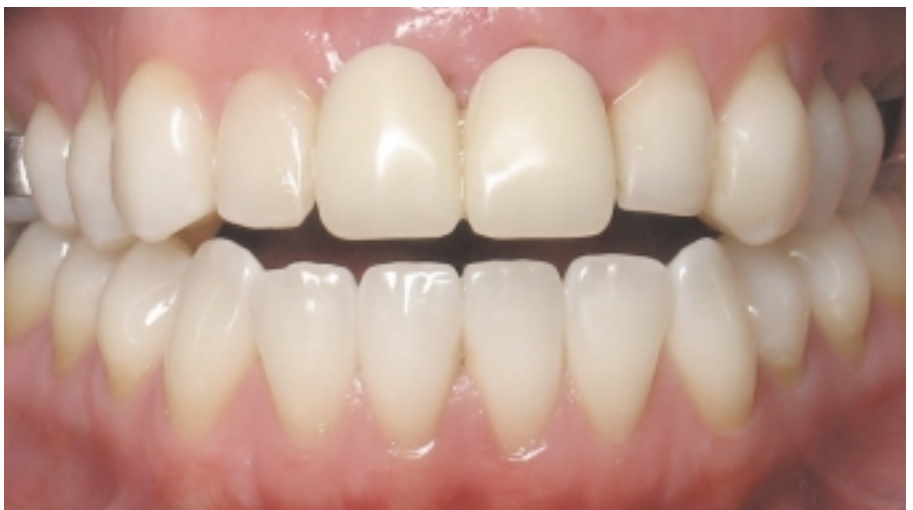**V**arious techniques are available to achieve optimal function and esthetics with provisional restorations.

Working together, both the restorative dentist and the periodontist should determine the proper technique that fulfills the specific requirement of each case.

Proper management will contribute to satisfying the patients' expectations and the success of osseointegration.

Provisional Prostheses Should:

- Provide a functional and stable occlusion.
- Restore and enhance esthetics and phonetics.



**Figure 1.** *A fixed / removable prosthesis can provide a very esthetic temporary restoration while minimizing trauma to the healing surgery site. (See Figure 2 on Page 2.)*

- Not interfere with primary wound closure.
- Protect the underlying gingival tissues.
- Not exert direct occlusal load on the underlying implants or bone-grafted sites.
- Determine the future position, support, shape and shade of the final prosthesis.

A well-designed provisional restoration is predicated upon three factors: the ultimate restorative plan, the number and location of the implants, and the needs and desires of the patient.

The most common forms of temporary restorations are fixed

bridges supported by retained natural teeth, resin bonded bridges, and removable interim prostheses.

The treatment objective is to protect the healing surgical site, provide adequate function and cosmetics, and to prevent micromovement of the implant and grafted site.

Preventing micromovement is essential to ensure osseointegration rather than fibrous encapsulation of the implant fixtures.

- **Using an existing prosthesis** is beneficial because it provides a transitional solution that was already esthetically and functionally satisfactory to the patient.

- It is sometimes advantageous to **maintain strategic “hopeless”**

**teeth** to support a fixed provisional bridge until such time as the restoration can be supported by osseointegrated fixtures.

- **Removable partial dentures**, while less than ideal for many reasons, do replace missing teeth and the flanges can provide necessary lip support. However, the inherent lack of stability may compromise function and speech, and encroach upon the surgical site.

Adding acrylic resin to the tissue surface of the anterior pontic of a removable provisional prosthesis can help shape the gingiva and potentially assist in the formation of papillae adjacent to the pontic.

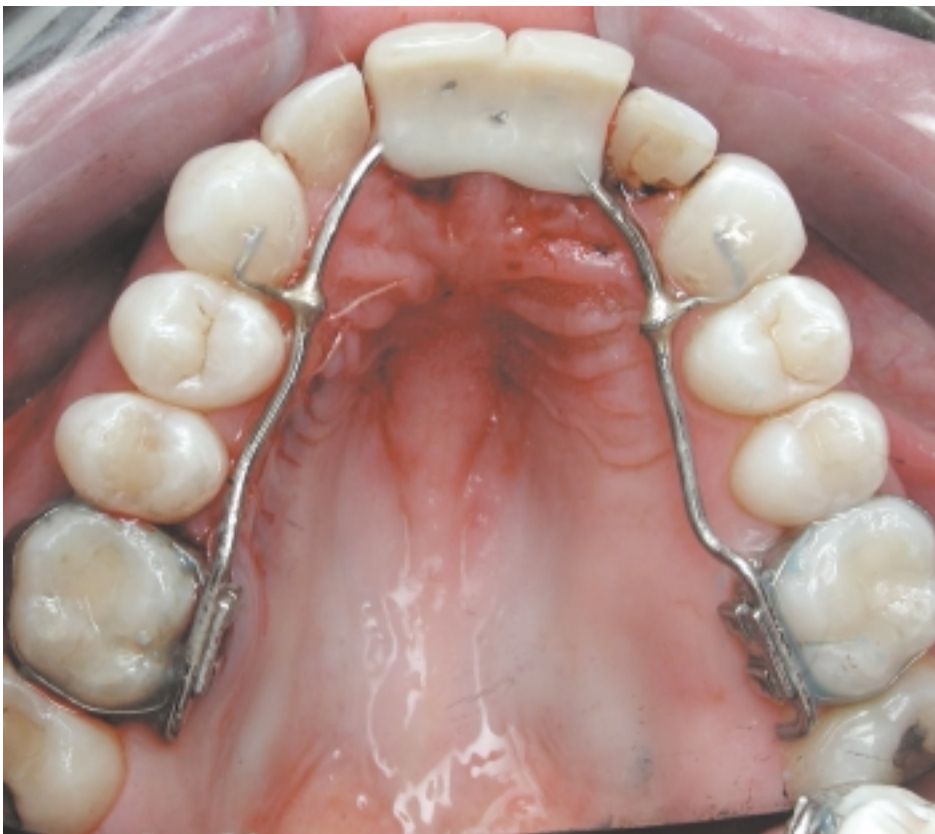Using this approach can assist in the development of a natural emergence profile for the implant-supported restoration.

This procedure should be performed with caution in order not to exert any unnecessary pressure to the underlying implants or surrounding tissues.

- **Adhesive Bridges:** Resin Bonded Restorations meet the requirements established for provisional implant restorations insofar as they are totally tooth-supported and retained by acid etched bonding. It is quite useful to bond the anatomical crown of the extracted tooth to the adjacent teeth. These restorations protect the implant site from occlusal loading, while providing functional occlusion and esthetics.

## Transitional Implants

Recently, mini transitional implants have been used to support fixed and removable provisional restorations. They have



*Figure 2. A fixed/removable temporary restoration utilizing orthodontic bands and palatal arch wire with occlusal rests. (See Figure 1 on Page 1.)*

proven to be effective in protecting implant surgical sites, as well as providing the other prerequisites of an acceptable temporary restoration.

These narrow diameter implants are similar to root form implants, providing immediate tooth replacement, and allowing the patient to immediately experience the positive benefits of implant dentistry.

Some important considerations when using transitional implants are as follows: One must maintain adequate space between “temporary” and “permanent” implants. Similarly, adequate space maintenance between transitional implants and natural teeth is essential. Furthermore, to prevent failure from occlusal overload, it is advisable to use an adequate number of mini implants to support the interim prosthesis.

Transitional implants appear to be more successful in the mandible

than the maxilla. It has been suggested that this may be due to enhanced bone density in the mandible. This noticeable deficiency may be overcome by increasing the number of mini implants in the maxilla. Following confirmation of osseointegration of the permanent implants, the transitional implants can be easily removed.

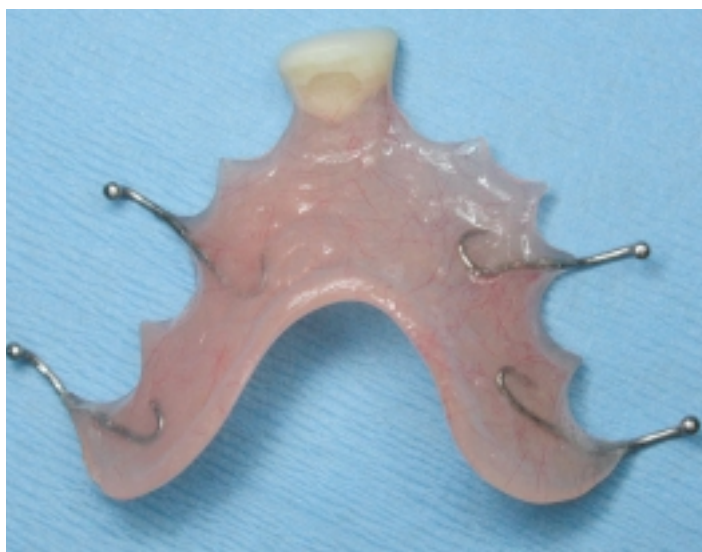If immediate loading of the implant is desired, three methods of provisionalization are commonly selected:

- A restoration may be delivered the day of implantation, or at the time of uncovering, by indexing the implant platform with a fixture level impression.
- A temporary cylinder or abutment can be used upon which to fabricate a provisional restoration.
- A laboratory processed acrylic tooth shell can be relined and adapted to a temporary or custom abutment.

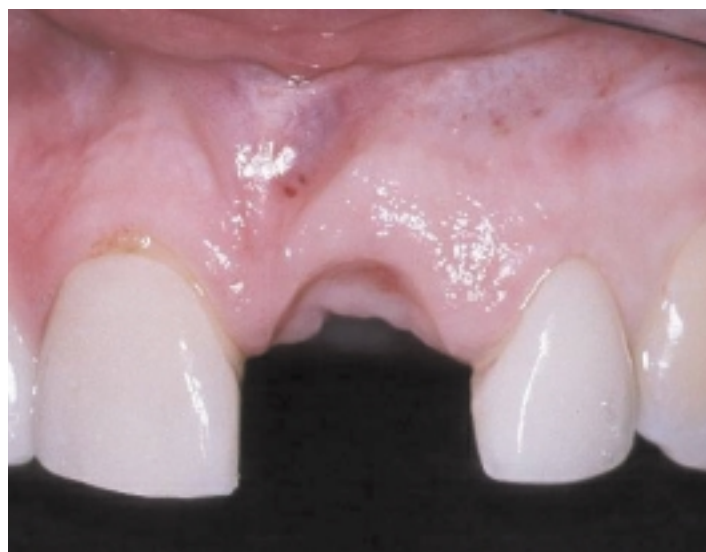## Other Methods of Provisionalization

The Essix appliance (Essix-Raintree), is a patient removable, temporary restoration, which avoids the many disadvantages of a partial denture. A vacuform shell of the arch is fabricated from a stone model, prior to the extraction of a tooth. The crown of the extracted tooth may be bonded into the retainer, or more commonly, tooth colored resin fills the space previously occupied by the crown of the extracted tooth. This appliance should fit snugly over the remaining teeth in the arch, which prevents unfavorable displacement or movement over the implant site/s.

Other creative methods of provisionalization involve a variety of orthodontic appliances. Prosthetic or natural tooth replacements may be attached directly to an existing arch wire, or to brackets which are



**Figure 3.** A removable, temporary partial with interproximal clasps to provide tooth support, retention and prevent pressure on a grafted implant site.



**Figure 4.** A temporary removable partial denture with an ovate pontic can not only be used to replace missing teeth but also to provide an ovate site in the gingiva while supporting the papillae.

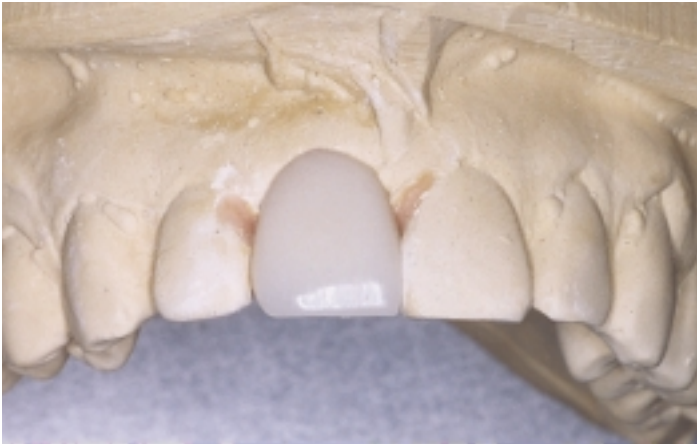
bonded to adjacent teeth with an inactive arch wire.

Another approach involves the use of a fixed-removable, palatal orthodontic appliance. This appliance permits a stable, provisional tooth replacement, which can easily be removed by lifting the provisional from the

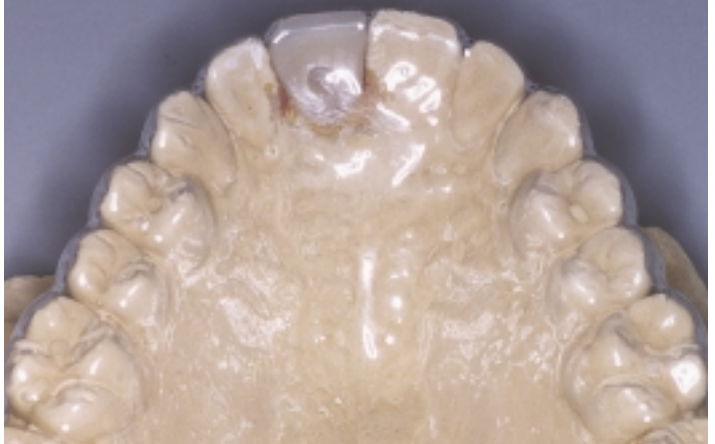palatal slots in the molar orthodontic bands.

The objective of an implant supported prosthesis is to provide a functional and cosmetically acceptable form of tooth replacement. An interim, provisional restoration is critical during the integration phase of the implant.

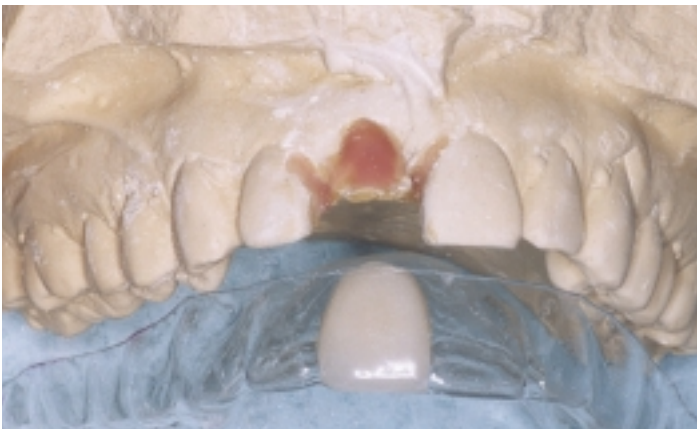A well-conceived appliance, produced by the restorative dentist and laboratory and designed in partnership with the periodontist, provides protection of the surgical site and continued function, without compromising esthetics.



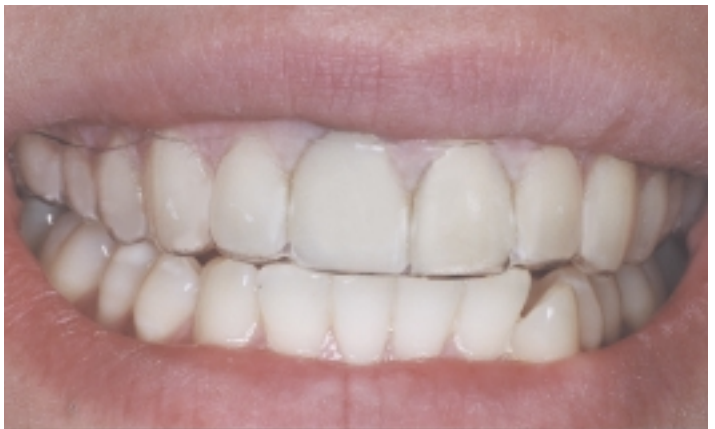*Figure 5. To create an Essix appliance, an artificial tooth is shaped to ideal form.*



*Figure 6. An acrylic vacuform tray is created over the tooth replacement.*



*Figure 7. The tray is reshaped for seating and the artificial tooth is bonded into the tray.*



*Figure 8. When the natural tooth is removed, the tray can be seated for a temporary replacement during implant healing.*