

From Our Office to Yours...

Tooth extraction often results in alveolar ridge resorption and soft tissue collapse.

Preservation of bone volume and soft tissue height at the time of tooth extraction is critical to ensure ideal bone and soft tissue contours. This will allow placement of an implant in the proper position to facilitate an esthetic implant restoration.

Proper management of extraction sites can reduce or eliminate the future need for advanced ridge augmentation procedures prior to implant placement.

Conversely, inadequate extraction site management may lead to esthetic, functional and prosthetic complications, as well as the ability to place an implant.

*This issue of **The PerioDontaLetter** presents an overview of extraction site management to minimize tissue loss and conserve the natural ridge form and architecture for future implant placement.*

As always, we welcome your comments and suggestions on the importance of site preparation for implants.

Extraction Site Management

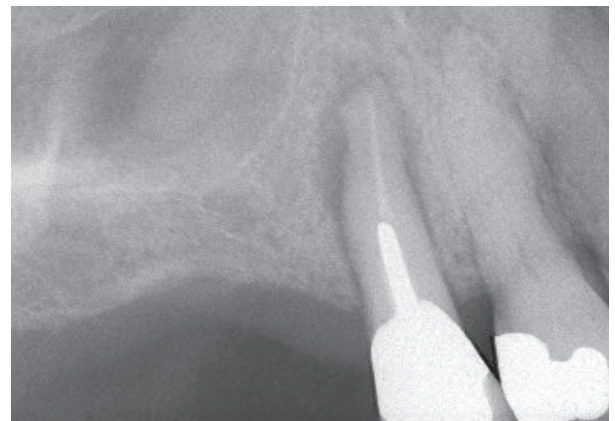Since osseointegration has become a highly predictable and frequently recommended procedure, implant success is now also defined by prosthetic demands — the factors that will produce a restoration in esthetic and occlusal harmony with adjacent oral structures.

The philosophy of “prosthodontically-driven implant placement” requires the clinician to first envision the final restoration in its ideal position. Therefore, it is crucial that as much of the patient’s natural and healthy alveolar dimensions be preserved during extraction.

Ridge Resorption Following Extraction

The normal post-extraction healing response of an alveolar socket is resorptive. Most of the literature suggests that the loss of alveolar ridge following tooth extraction occurs along the buccal aspect of the ridge and is greater in the horizontal dimension compared to the vertical dimension. Extraction can result in 40 to 60% of dimensional reduction within the first six months following extraction. This in turn can contribute to esthetic compromises caused by less than ideal implant placement.

Figure 1. The upper first premolar was diagnosed with a cracked root. (See Figures 2 and 3 on page 2.)



Preservation of the residual alveolar bone is also critical to prevent soft tissue recession and loss of normal papilla anatomy which are almost impossible to surgically recreate after being lost.

Minimally Invasive Tooth Removal Techniques

Minimally invasive tooth extraction is accomplished by gently severing the periodontal attachment and being careful not to fracture the delicate buccal plate. This is accomplished using specially-designed, non-traditional micro-instrumentation. New forceps that precisely fit the contours of each tooth securely engage the roots of teeth in which the crown has been substantially compromised.

Instead of the conventional buccal-lingual luxating method, a 30-second gentle, circumferential rotation is used to stretch and weaken the periodontal ligament. This method of luxation stimulates the release of lysosomal enzymes and bleeding into the periodontal ligament space, initiating a process to loosen the periodontal ligament fibers.

A thin bladed knife or periosteal elevator is used to sever the gingival attachment

and most coronal portion of the periodontal ligament. When the tooth is sufficiently mobile, it may be gently removed.

The Role of Socket Grafting

Socket grafting at the time of extraction has been proven to preserve the original alveolar architecture by limiting the post-extraction resorption process. Many studies indicate that a greater amount of socket resorption can be expected without a graft. Initial socket grafting can prevent the need for a secondary bone augmentation procedure.

Many types of regenerative material are available. Choosing the correct material depends largely upon alveolar bone defect morphology and clinical preference. Bone grafting materials fall into one of four categories:

1. **Autogenous bone grafts** — bone derived from the recipient.
2. **Allogeneic bone grafts**, or “allografts”— derived from a human other than the recipient.
3. **Xenogenous bone grafts** — grafting material harvested from a different species, typically bovine or equine grafts.

4. **Alloplasts** — derived from synthetic sources.

Depending on which bone grafting material is used, the bone-rebuilding process can be:

- **Osteoconductive** — forming a framework around which new bone grows.
- **Osteoinductive** — stimulating new bone growth and healing.
- **Osteopromoting** — accelerating the healing of bone by attracting osteoblasts and fibroblasts to the area.
- **Osteogenesis** — forming completely new bone.

Biologic modifiers and allograft stem cell cultures are also commonly used in combination with particulate materials. These have demonstrated enhanced results compared to bone grafts alone.

Socket Repair

Even with socket grafting, buccal bone resorption still occurs in many extraction sockets necessitating additional attempts to create natural ridge anatomy.

Elian et al proposed a simplified classification system for extraction sockets:

Type I: Both the soft and hard tissue are intact. These sites lend themselves to simultaneous extraction and immediate insertion of the implants.

Type II: Buccal bone loss, but no soft tissue loss. Bone grafting such extraction sites requires the use of a membrane to contain the bone grafting material, as well as provide a barrier for the exclusion of soft tissue growth in to the grafted site.

Type III: Both soft tissue and bone loss on the buccal. These extraction sites are the most complex to treat, and will always require a staged approach with bone and soft tissue augmentation.

Outcomes of human clinical studies on ridge preservation techniques suggest:

1. Allowing three months of healing after tooth extraction and ridge preservation using mineralized bone allo-

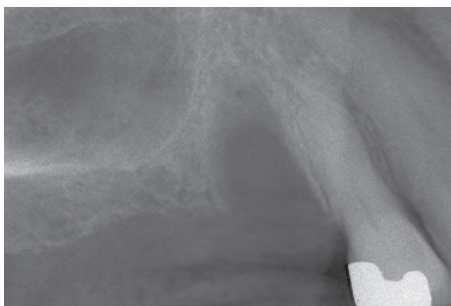

Figure 2. The tooth was removed without any attempt at ridge preservation.

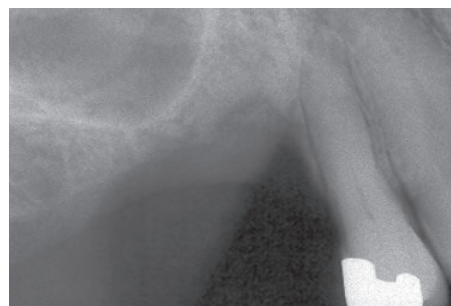


Figure 3. The post-healing radiograph reveals severe ridge resorption in the healed extraction site.

graft provides new bone formation similar to that formed after six months. (Beck and Mealey)

2. When comparing mineralized to demineralized bone grafts, there was no difference in ridge dimensional changes; however, the demineralized grafts showed a higher percentage of new bone and a lower percentage of residual graft particles. (Wood and Mealey)

3. When comparing mineralized to a 70/30% combination of mineralized/demineralized bone grafts, there was no difference in ridge dimensional changes; however, the demineralized grafts showed a higher percentage of new bone and a lower percentage of residual graft particles. (Borg and Mealey)

4. When comparing cortical to cancellous bone grafts, there was no difference in the amount of new bone formation, but more residual graft particles remained in the cortical graft group. (Eskow and Mealey)

Provisional Restorations

Provisional restorations are another way to preserve the existing architec-

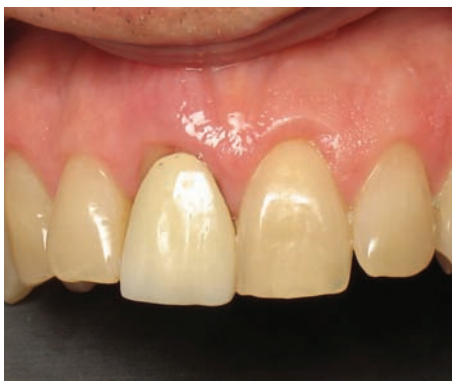

Figure 4. The upper right central incisor was diagnosed as hopeless and needed to be removed.

ture of the extraction site and minimize further soft tissue loss.

Immediate placement of an implant within the extraction socket restored with a non-functional provisional restoration is thought to enhance the maintenance of the pre-existing subgingival form.

Screw retained provisional restorations offer flexibility in maintaining or modifying tissue contour. Utilizing screw-retained transitional restorations eliminates the possibility that subgingival cement will interfere with the healing of the implant.

Most importantly, provisional restorations shape and “train” the peri-implant tissues to help the laboratory fabricate an anatomically appropriate and esthetic soft tissue model.

Provisional restorations protect the underlying gingival tissues and the healing implant site from excessive occlusal pressure. They also can aid in determining the future position and shape of the final prosthesis.

Restoration-Driven Tissue Regeneration

Regenerating the peri-implant tissues, particularly the interdental

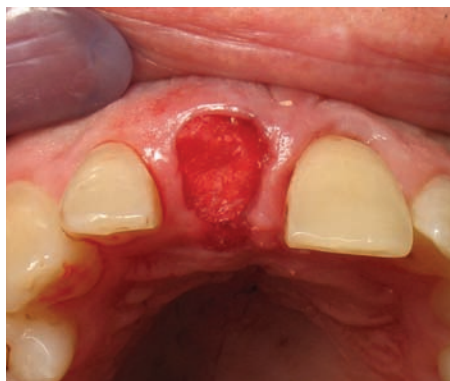


Figure 5. Following atraumatic extraction, the socket was debrided, a bone graft was placed and covered with a resorbable membrane.

papillae is essential to obtaining optimal esthetics for implant-supported restorations. In many patients, the osseous topography resulting from tooth loss is flattened and does not readily support the complete re-formation of interproximal papillae. This can result in a “black triangle” between the implant-supported restoration and adjacent teeth.

Prior to extraction, the gingival biotype should be assessed to determine the risk for post-surgical gingival recession. A thin, highly scalloped gingival biotype is much less resistant to trauma from surgical procedures and, consequently, is more prone to recession in comparison with a thick, flat gingival biotype.

Immediate and Delayed Implant Placement

Immediately placed implants in extraction sockets can minimize bone resorption and assist in maximizing esthetic results. Studies have shown a comparable success rate of delayed and immediately placed

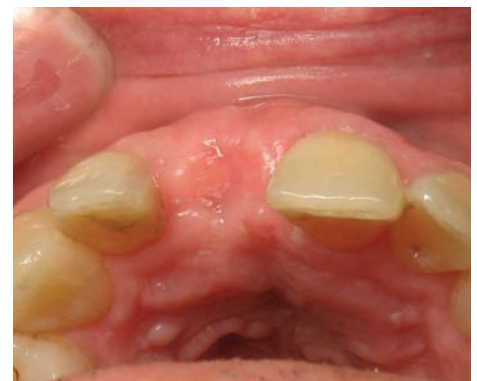

Figure 6. Upon healing, ridge dimensions were preserved allowing for ideal implant placement.

implants with respect to bone height, tissue preservation and esthetics.

An immediate implant is initially mechanically stabilized in the bone by the implant shape and thread design. Usually the site is grafted at the same time with a resorbable or non-resorbable membrane that excludes soft tissue, allowing the bone grafted socket site to heal nor-

mally with the newly forming bone around the implant thus providing biologic stability.

Occasionally, an early “delayed” implant placement protocol (four to six weeks after extraction) is used to allow initial soft tissue healing or reduction of infection within the socket. Bone augmentation is deferred until the time of implant

placement within the socket as the short delay does not impact bone resorptive changes.

Conclusion

Resorption of the residual ridge begins once the tooth is extracted, and it is in the best interest of our patients that prior to extraction we have a management strategy in place.

Working in concert with our restorative dental colleagues, we can preserve sufficient alveolar bone to place an implant in a position to facilitate a functional and cosmetically acceptable tooth replacement.

Regardless of the clinical situation, the bony and soft tissue foundations for dental implants should be evaluated prior to the removal of teeth.

Management strategy should be discussed with the patient before treatment begins in addition to determining realistic expectations from the treatment.

Certain medical conditions, tobacco use and adverse pressure from interim prostheses may result in compromised healing response and surgical results

Each step during treatment should be regarded as part of a continuum. When multiple practitioners are involved, each should be kept informed of treatment decisions as well as treatment progress.

The most cost-effective and time-efficient bone augmentation procedure available remains the preservation of the alveolar dimensions at the time of extraction.

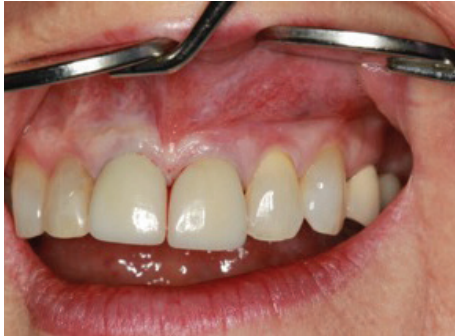

Figure 7. The maxillary left central incisor had a cracked root and an extremely large apical infection.

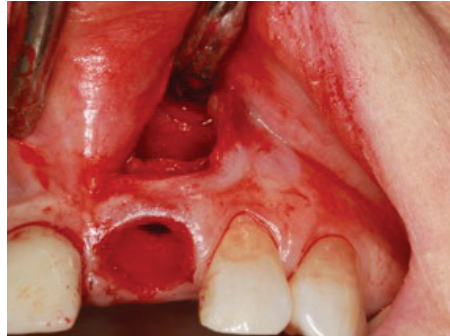

Figure 8. The tooth was removed atraumatically and the apical defect exposed and debrided without involving the interproximal papillas.

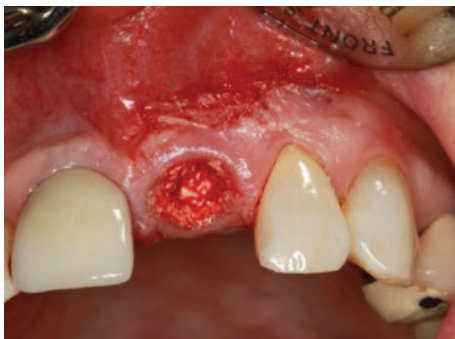

Figure 9. The apical defect and socket were grafted to prevent collapse of the labial-lingual dimension.

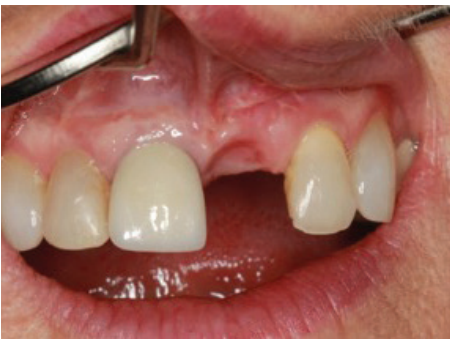

Figure 10. Final healing prior to implant placement.

