

From Our Office to Yours...

As dentists specializing in treatment of diseases of the oral cavity and associated structures, we are often also called upon to treat painful oral lesions in the mouth. This issue of The PerioDontaLetter contains guidelines on how to treat these common oral lesions.

The back page of this issue contains a table summarizing the confusing array of bisphosphonates and monoclonal antibodies which are used to treat osteoporosis and bone cancer. This table includes the route these drugs are administered, and their likelihood of causing drug-induced osteonecrosis of the jaws – a side effect which we clinicians need to be aware of in treating our patients who are taking these drugs.

We hope you find this information helpful.

As always, we welcome your comments and questions.

A Concise Guide to Treating Painful Oral Lesions

Patients present frequently with painful oral lesions. They are usually not serious, but patients appreciate our attention to them, our reassurance they are not serious, and specific prescriptions for treatment. There is usually no cure, but there are treatments that shorten their duration and reduce the pain. Some of these are recurrent and others are self-induced such as toothbrush trauma and burns from hot foods.

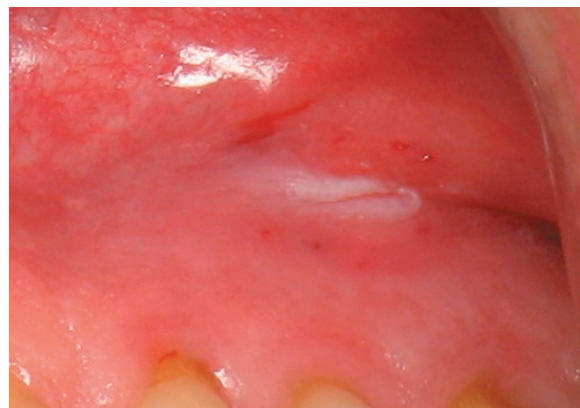
Always be mindful of looking for oral cancer, and biopsy any suspicious lesion.

Treating Cold Sores And Canker Sores

If the sore is **on the lip**, it is caused by a **herpes virus infection** and is contagious. These are commonly called “**cold sores**” or “**fever blisters.**” Patients should avoid touching them and then touching their eyes since the herpes virus can spread to the eye and then is much more difficult to treat.

Treatment: Over the counter Abreva crème applied five times a

*Figure 1.
Recurrent aphthous
ulcers occur on
moveable oral
mucosa inside the
mouth and are not
contagious.*



day will shorten their duration. Over the counter Carmex lip balm applied at the first tingle will help the pain. Valtrex can be prescribed — two grams in the morning and two grams in the evening — taken at the first sign of an outbreak. Zovirax or Denavir ointments can also be prescribed, but are very expensive (\$800-\$900 per tube) and often not covered by medical insurance. A local compounding pharmacist can make up a much less expensive generic version of Zovirax (5.5% acyclovir ointment).

The most common sore **inside the mouth** is an **aphthous ulcer**, commonly called a “**canker sore**.” These are not viral, occur on movable tissue like the tongue or cheeks, and are not contagious. The cause is unknown and they tend to recur.

Treatment for individual sores includes application of over-the-counter (OTC) Zilactin B, Canker-X, Orajel with benzocaine, or prescription Orabase with the steroid Kenalog. These coat and numb the lesion. The prescription steroid ointment Lidex is another possibility. In office, Debacterol can be applied which will cauterize the lesion and reduce the pain.

For multiple canker sores, treatment with the so-called “Magic

Mouthwash” containing Benadryl, Maalox, and viscous xylocaine will reduce pain dramatically. For larger outbreaks, the steroid dexamethasone can be added to the mixture. These mixtures are compounded by a local pharmacist. Alternatively, prescription dexamethasone elixir alone, 0.5mg/ml, can be used as a rinse — one tablespoon for two minutes four times a day — or OTC Rincinol can be used as a rinse to coat the lesions.

Treating Generalized Painful Ulcerations

More **generalized**, or occasionally localized, blood-filled erosive lesions with the tissue sloughing (Nikolsky’s sign) sometimes form on the gums and cheeks. These are usually caused by **Desquamative Gingivitis (Benign Mucous Membrane Pemphigoid)**. Generalized or localized painful erosive lesions on the cheeks or tongue characterized by **white striations** are caused by **Erosive Lichen Planus**. These are both considered autoimmune diseases, and treatment is palliative not curative.

Treatment: An anti-oxidant gel called PerioSciences AO ProVantage Antioxidant Gel can be applied five times a day for mild cases. For more

severe cases, a steroid gel called Clobetasol 0.05% (15gm tube) can be prescribed and applied with a Q-tip twice daily. Alternatively, dexamethasone elixir 0.5mg/ml (12 oz. bottle) can be used as a rinse, one tablespoon for two minutes four times per day. In severe cases, this rinse can be used in combination with Clobetasol gel. For Desquamative Gingivitis, doxycycline 100 mg once a day for 30 days has been found very useful.

These conditions are a sometimes-painful annoyance, but are not serious and recurrence is common. If not painful, no treatment is needed.

Primary Herpes Infection will sometimes occur, most often in children, but occasionally in adults. This infection is characterized by very **painful ulcers throughout the mouth**, including the gums and throat. It is often accompanied by fever, swollen lymph nodes, difficulty eating and fatigue. The outbreak usually lasts from seven to 14 days and then goes away on its own. It is a very painful, but not a serious condition. It is contagious during the outbreak.

Treatment: prescription Valtrex, 500 mg, take two caplets twice daily for five days. Treatment with the so-called “Magic Mouthwash” containing Benadryl, Maalox and viscous xylocaine will reduce pain dramatically. Chloraseptic spray can numb the tissue before eating.

Pemphigus Vulgaris causes **more serious**, diffuse, very painful ulcerations throughout the mouth, and on the skin, and requires a special immunofluorescent biopsy to diagnose. Fifty percent of patients with this condition present first with oral lesions before the onset of skin lesions resembling a burn.

Treatment: This is a serious condition and requires management by a dermatologist, often with systemic steroids.

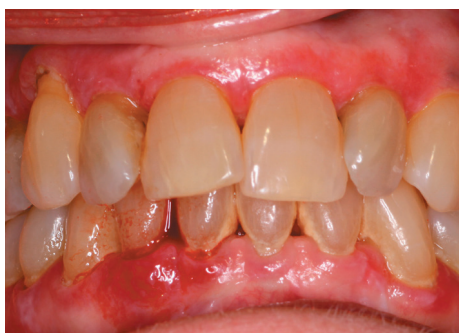

Figure 2. Desquamative Gingivitis produces generalized blood-filled erosive lesions with tissue sloughing (Nikolsky’s sign).

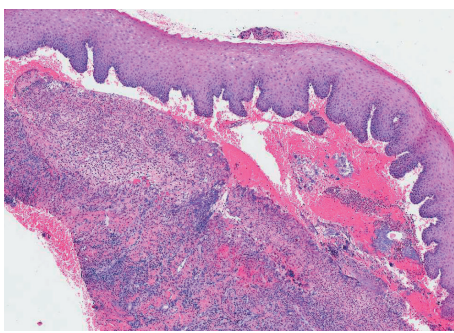


Figure 3. Histological section reveals separation of the epithelium due to lack of adhesion along the basement membrane.

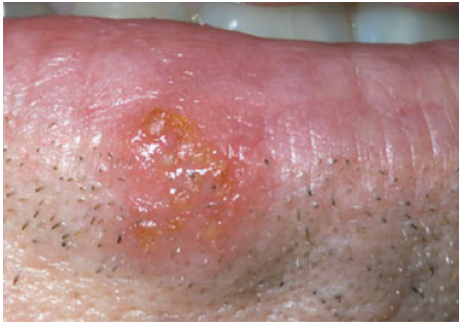

Figure 4. Herpes virus infection occurs on the lip and is contagious. Primary herpes infection occurs inside the mouth.

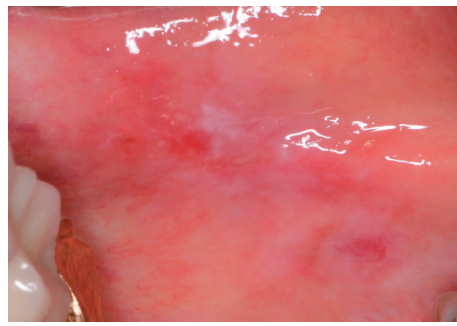


Figure 5. Erosive Lichen Planus occurs on the cheeks or tongue and is characterized by white striations.

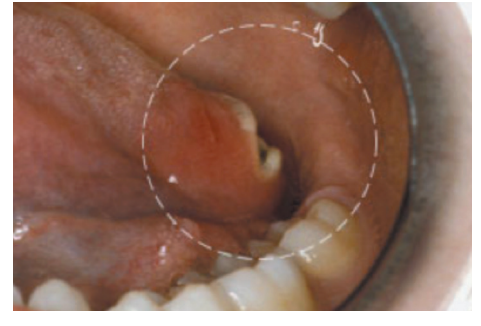


Figure 6. Oral Cancer occurs most commonly on the base of the tongue or in the throat. Early diagnosis is critical.

Treating Yeast Infections

Sores on the **corners of the mouth** are called **Angular Cheilitis** and cause pain when opening and closing the mouth. These sores are usually caused by a yeast infection (*Candida albicans*) secondary to wear or loss of teeth. The loss of teeth in turn causes overclosure of the mouth, creating a crease at the corners of the mouth where saliva accumulates.

Treatment of Angular Cheilitis:

Patients should avoid licking the area with their tongue. They should keep the corners of their mouth dry by dabbing frequently with a facial tissue. Prescription Mycolog-II ointment is then applied four times a day until healing occurs. Alternatively, OTC Monostat 7 vaginal cream can be applied four times a day.

Inside the mouth, yeast infection is usually characterized by white patches that often can be scraped off. Occasionally, it shows up as red patches, or as a black, hairy tongue. This infection is usually caused by prolonged antibiotic use, steroid inhalants, or lowered immune system.

Treatment of yeast infections inside the mouth: Mycelex troche (clotrimazole) 10 mg allowed to dis-

solve in the mouth five times a day for 14 days. An alternative is Nystatin oral suspension (100,000 units/ml-dispense 240 ml), take one teaspoon and swish for two minutes, then swallow, four times a day. For more severe yeast infections, Diflucan 100 mg can be prescribed -- 15 tablets, take two tablets, then one tablet daily for 13 days.

Diagnosing Oral Cancer

Lesions that may be oral cancer include **a sore in the mouth that doesn't heal**, a lump that does not go away, a white patch anywhere in the mouth, difficulty swallowing, or a swollen lymph node in the neck. The gold standard is to **biopsy any suspicious lesion**. Sometimes, a special fluorescent light can be used to help screen for cancer and determine if a biopsy is indicated.

Risk factors for oral cancer are **smoking**, excessive alcohol consumption, and especially chewing tobacco or snuff. Chewing tobacco increases the risk of oral cancer by a staggering 50 times. Stopping any of these habits will substantially reduce the risk of oral cancer.

An emerging risk factor is **Human Papillomavirus (HPV16) infection**,

a sexually transmitted virus which is causing throat cancer in younger people. Testing positive for HPV16 means you are at greater risk of throat cancer and need to be monitored more closely. These cancers occur most commonly on the **base of the tongue or in the throat**, so these areas need to be examined thoroughly during an oral cancer examination. A simple salivary DNA test can determine if a patient is HPV positive. The Centers for Disease Control recommends that all boys and girls between the ages of 12 and 26 be vaccinated against HPV16, ideally prior to sexual exposure to the virus.

Oral cancer kills more people annually than cervical or prostate cancer. Oral cancer has only a five percent survival rate at five years. If found early, survival increases dramatically, so any suspicious lesion should be examined, and possibly biopsied, as soon as noticed.

Conclusion

We have reviewed the diagnosis and management of the most common painful oral lesions that you will encounter in daily practice. We hope this information will assist you in their diagnosis and treatment.

Drugs Used to Treat Osteoporosis and Bone Cancer Which May Cause Osteonecrosis of the Jaws

The many bisphosphonates and monoclonal antibodies which are used to treat osteoporosis and bone cancer often cause osteonecrosis of the jaws. As dental clinicians, it is important that we are aware of this side effect before treating our patients who are taking these drugs. The tables below summarize these drugs, the route these drugs are administered, and their likelihood of causing osteonecrosis of the jaws as reported by Dr. Robert Marx at the University of Miami Division of Oral and Maxillofacial Surgery.

Drugs Used to Treat Osteoporosis

Drug	Classification	Action	Dose	Route	% of Reported Cases of Osteonecrosis
Alendronate (Fosamax Generic)	Bisphosphonate	Osteoclast Toxicity	70 mg/wk	Oral	82%
Residronate (Actonel Atelvia)	Bisphosphonate	Osteoclast Toxicity	35 mg/wk	Oral	1%
Ibandronate (Boniva)	Bisphosphonate	Osteoclast Toxicity	150 mg/mos	Oral IV	1%
Zoledronate (Reclast)	Bisphosphonate	Osteoclast Toxicity	5 mg/yr	IV	6%
Denosumab (Prolia)	Monoclonal Antibody	Osteoclast Impairment	60 mg/6 mos	Subcutaneous	10%

Teriparatide (Forteo) and raloxifene (Evista) are also used to treat osteoporosis but work differently, so they don't cause osteonecrosis and no special precautions are necessary.

Drugs Used to Treat Bone Cancer

Drug	Classification	Action	Dose	Route	% of Reported Cases of Osteonecrosis
Zoledronate (Zometa)	Bisphosphonate	Osteoclast Toxicity	4 mg/mo	IV	67%
Pamidronate (Aredia)	Bisphosphonate	Osteoclast Toxicity	90 mg/mo	IV	18%
Bevacizumab (Avastin)	Monoclonal Antibody	VEGF Inhibitor	100-400 mg/ 14 days	IV	<1%
Sunitinib (Sutent)	Tyrosine Kinase Inhibitor	Osteoclast Toxicity	5 mg/yr	IV	<1%
Denosumab (Xgeva)	Monoclonal Antibody	Osteoclast Inhibitor	120 mg/mo	IV	15%

