

From Our Office to Yours...

Implant-supported overdentures have been a common treatment for edentulous patients for the past 20 years and predictably achieve good clinical results. Many patients, especially those who are uncomfortable with dentures, enjoy the additional retention and support implants provide for their dentures.

The implant-supported overdenture has been accepted as the standard of care for fully edentulous patients and should be the first choice of treatment for the edentulous mandible.

In this issue of The PerioDontaLetter, we discuss the many advantages of implant-supported overdentures over conventional dentures and the survival and success rates of implants supporting overdentures in the maxilla and mandible, along with the various factors which influence them.

As always, we welcome your suggestions and comments and are available to team treatment plan implant-supported overdentures for your patients.

Implant-Supported Overdentures: The Standard of Care for Edentulous Patients

Implant-supported overdentures offer many practical advantages over conventional complete dentures and removable partial dentures. These include decreased bone resorption; reduced or eliminated prosthesis movement; better esthetics; improved tooth position; better occlusion, including improved occlusal load direction, increased occlusal function and maintenance of the occlusal vertical dimension. In addition, implant-

supported overdentures improve phonetics, the patient's psychological outlook and quality of life.

Conventional dentures rely upon the residual alveolar ridge and mucosa for support and retention. Many patients have problems adapting to their complete dentures, especially to the mandibular prosthesis. The widespread use of denture adhesives is one indication that these prostheses generally provide inadequate comfort and function.

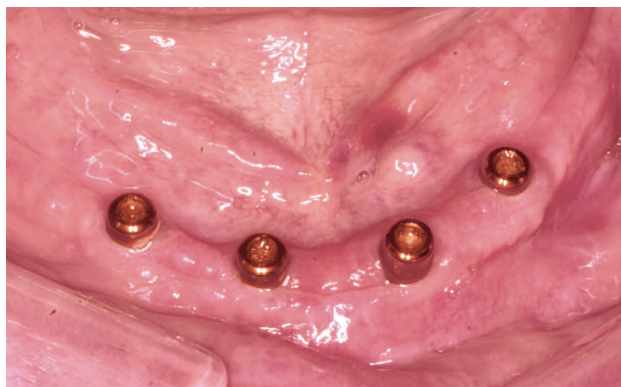

Figure 1.
Four implants were placed in a moderate to severely resorbed mandible in preparation for an overdenture.

Studies show implant-supported overdentures have superior retention to conventional dentures. Regardless of the type of attachment system used -- bar, ball or magnet -- patients are significantly more satisfied with implant-supported overdentures than with conventional dentures.

Patients find implant-supported overdentures significantly more stable and rate their ability to chew a wider variety of foods as significantly easier, thus improving their nutritional state. Furthermore, they find implant-supported overdentures more comfortable and speech easier.

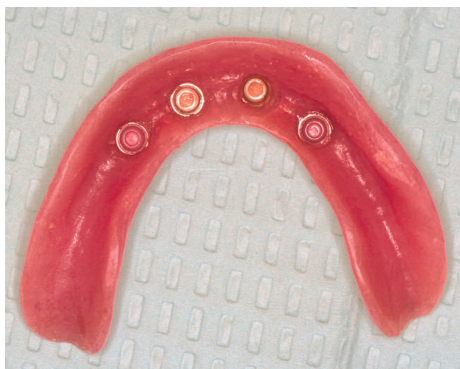

Figure 2. Locator attachments were placed in the implants and the overdenture.

The implant-supported overdenture may reduce the amount of soft tissue coverage and extension of the prosthesis which is especially important for new denture wearers or those who have low gagging thresholds.

The 2002 McGill Consensus Statement cites studies of several populations showing that patients with implant-supported overdentures enjoy a significantly higher quality of life than those who wear conventional dentures. The McGill Statement concluded there is overwhelming evidence that the restoration of the edentulous mandible with a conventional denture is no longer the most appropriate choice of prosthetic treatment. The implant-supported overdenture **HAS BECOME** the standard of care.

Numerous studies show cumulative success rates for all implant-supported overdentures at 95.4 percent, with implant-supported overdentures placed in the mandible enjoying a slightly higher success rate than implant-supported overdentures placed in the maxilla.

The major indications for a mandibular implant-supported over-

denture are lack of retention or stability, poor function and speech, tissue sensitivity and soft tissue abrasions.

Less Bone Resorption

One advantage of implant-supported full bridges and dentures is that they function like tooth roots, which preserves jaw bone. Dental implants integrate with the jawbone and dramatically reduce the rate of bone loss attributed to conventional dentures.

Edentulism is characterized by atrophy of the jaw bone. Studies show rapid resorption -- an average of 4mm -- occurs during the first year after tooth loss and thereafter decreases to 0.5mm per year. Over a five-year period, 5.2mm of vertical bone height will be lost under complete dentures. Bone loss under complete dentures continues with the mandible experiencing a fourfold greater vertical bone loss than the maxilla.

In contrast, Schwartz-Arad et al found that 70 percent of their patients with implant-supported overdentures lost less than .2mm bone in the first year. Misch found that only .6mm. of bone will typically be lost over a five-

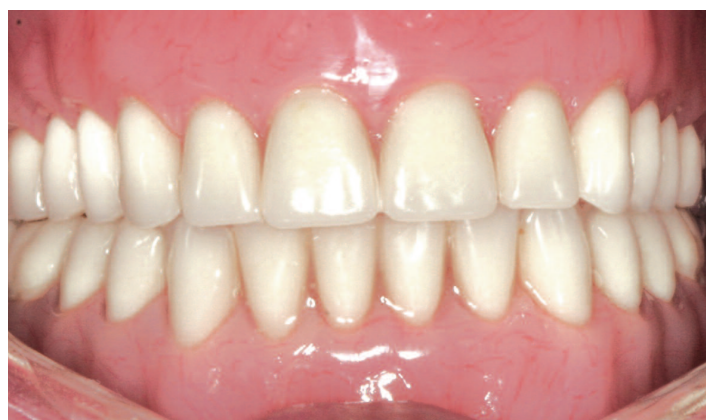

Figure 3. Final placement of the removable prosthesis resulted in a very attractive esthetic result and excellent function for the patient.

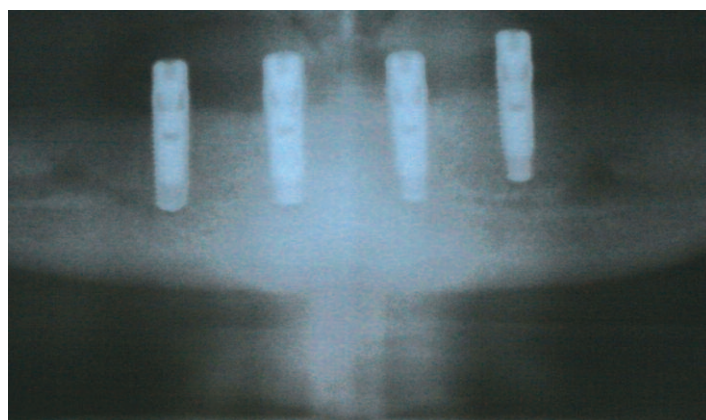


Figure 4. A final radiograph shows implant placement and apparent osseointegration.

year period and long-term resorption may remain as low as .1mm per year in patients with overdentures supported by multiple implants.

Crestal bone loss (CBL) around implants supporting overdentures appears to be affected by factors such as location (maxilla or mandible), attachment system, and number of implants supporting the overdenture.

Location in the maxilla or the mandible appears to most influence CBL. Studies show implants in the mandible exhibit less CBL than implants in the maxilla, which could be attributed to the difference in bone quality in the maxilla and the mandible and to different loading circumstances.

The maxilla normally has less density and quantity of bone than the mandible. The resorbed mandible usually has dense compact bone with an oak-like quality or a combination of thick porous compact bone on the outside and coarse trabecular bone on the inside. Because the percentage of bone at the implant interface is 70 to 80 percent, mandibular implants are the most successful.

The type of bone most commonly found in the long-term edentulous

maxilla is a combination of thinner porous compact bone on the outside and fine trabecular bone on the inside, or fine trabecular bone with very light density and little or no cortical crestal bone. The amount of bone at the implant-to-bone interface ranges from 50 percent down to 25 percent making maxillary implants less successful.

Timing of implant loading appears to be a factor in the success of implant-supported overdentures. Immediate loading techniques, a newer approach to implant-supported restorations, depends on many factors and requires precise coordination between the periodontist and the restorative dentist.

Recently, more two-implant mandibular overdentures are being placed as an affordable alternative to prostheses requiring several implants. The choice of implant site for these overdentures should be governed by the quantity, quality and volume of available bone, along with the size and curvature of the anterior arch.

As it is with all implants, the success rate of implant-supported overdentures was lower among patients who used tobacco. CBL did not

appear to be affected by implant length, diameter or surface.

The study showed implants with increased CBL initially regarded as failing implants could become successful after an extended follow-up period of more than three years. Qyuirynen et al found that the progression of bone loss around implant-supported mandibular overdentures decreases with time.

Resorption also causes changes in bone shape making it necessary to continually repair and remake conventional dentures. These changes are indications for the success of implant-supported overdentures which do not require continual repairs and remanufacturing.

Greater Prosthesis Stability

The greater stability of an implant-supported overdenture derives from the mechanical attachment of the implant support system retaining the restoration.

A mandibular denture may move 10mm during function. Under these conditions, predetermined occlusal

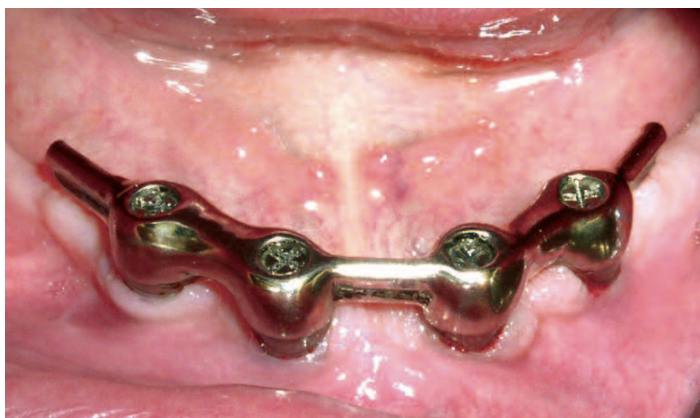

Figure 5. Four implants were placed to attach a fixed bar.

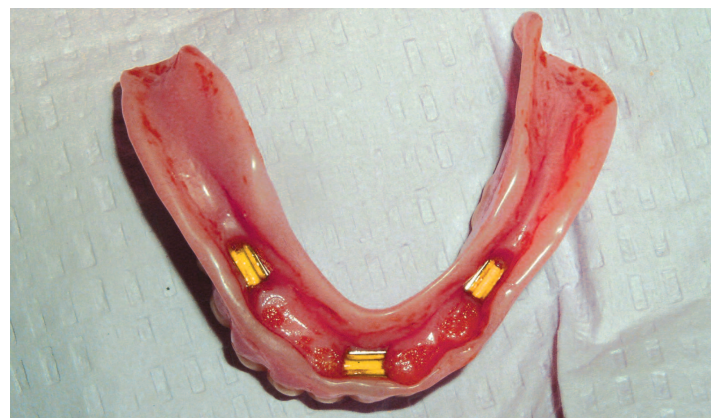

Figure 6. Three clips were placed in the overdenture for retention.

contacts and the control of masticatory forces are nearly impossible. Implants stabilize the prosthesis and the patient is able to consistently reproduce a determined centric occlusion. Lateral forces may cause a horizontal movement of a conventional prosthesis and cause soft tissue abrasions and accelerated bone loss. An implant-supported overdenture limits lateral movements and consequently minimizes soft tissue trauma.

In addition, complete dentures often move vertically during mandibular movement and speech. The contraction of the mentalis, buccinator, or mylohyoid muscles may lift the denture off the soft tissue. As a consequence, the teeth may touch during speech and cause clicking noises.

The implant-supported overdenture remains in place during mandibular movement which allows the tongue and perioral musculature to resume a more normal function since they are not required to control mandibular denture movement.

While prosthesis retention has been found to be good for magnets, balls and clips, bars were the most retentive. Studies have shown balls experienced more complications.

Overdenture bars may be cemented or screw-retained. Cemented bars present the advantages of more passive fit, reduced cost and an easier bar impression technique.

Jemt et al showed a decrease in occlusal force when the bar connecting implants was removed and attributed it to the loss of support, stability and retention.

The prosthesis support and range of motion should be part of the initial diagnosis. Proven, simple, pre-

dictable and cost-effective devices limited to a minimum of hardware may present the best options. The more sophisticated the attachment, the more complex the fabrication and maintenance procedures.

Better Esthetics, Tooth Position and Occlusion

In severe resorption cases, implant-supported overdentures may be more esthetic than a fixed restoration. Bone loss dictates the appearance of the inferior third of the face. An implant-supported overdenture provides improved support for the lips and soft tissues of the face allowing the teeth to be the same length as natural teeth. When there is marked loss of alveolar height, the teeth on a conventional fixed restoration will be very long.

The presence of a large labial flange in a conventional denture may result in exaggerated facial contours for the patient with recent extractions. Implant-supported prostheses do not require as great a labial extension or as much extended soft tissue coverage as is necessary for a conventional denture. An implant-supported overdenture can provide the soft tissue support to the facial features often required for a patient with advanced bone loss.

Traditional tooth-supported overdentures must rely on the remaining teeth to support the prosthesis. The location of these natural abutments is highly variable and they are often compromised from past bone loss associated with periodontal disease.

This is not the case with implant-supported overdentures. For implant-supported overdentures, the implants

may be placed in the anterior positions of choice. The number, location, superstructure, design and prosthetic range of motion can be predetermined and based on a patient's expressed needs and desires as opposed to conventional, fixed restorations which may have to be placed in a specific mesiodistal location because the prosthesis does not completely cover the abutment.

Misch found the maximum occlusal force of a patient with dentures may improve 300 percent with an implant-supported prosthesis. This improves the chewing efficiency of patients with an implant-supported overdenture by 20 percent over the bite strength of patients with a conventional denture. Misch also cites a study of chewing efficiency comparing complete denture wearers with implant-supported overdentures. Patients with conventional dentures needed 1.5 to 3.6 times the number of chewing strokes as patients with implant-supported overdentures.

Improved Maintenance

Hygiene conditions and home maintenance procedures are improved with an overdenture compared with a fixed prosthesis. The overdenture may be extended over the abutments to prevent food entrapment during function.

Professional maintenance is also improved as peri-implant probing is diagnostic and easier around a bar.

We hope this review of the significant advantages implant-supported overdentures offer over conventional dentures has been helpful to you in treatment planning for your edentulous patients.

