

From Our Office to Yours...

The benefits of the use of computed tomography (CT/CBCT) technologies in dental implant surgery are widely known.

Less well known is the wide range of applications of CT technologies in the diagnosis and treatment planning of other dental conditions.

CBCT scanning is widely used in oral and maxillofacial surgery, orthodontics, periodontics, endodontics, restorative and forensic dentistry, and in the diagnosis and treatment of temporomandibular joint dysfunction (TMJ). For many dental applications it has become the standard of care.

*This issue of **The PerioDontaLetter** will review the many ways in which the dental cone beam CT scanner can be used to diagnose and treat dental problems where the third dimension is essential in understanding how to best treat our patients.*

As always, we welcome your comments and suggestions on this significant advancement in dental imaging.

The Many Clinical Applications of Cone Beam Computed Tomography

While dental imaging techniques have advanced with the introduction of tomography and panoramic imaging, 2D images possess inherent limitations, including magnification, distortion, and superimposition, that can misrepresent structures.

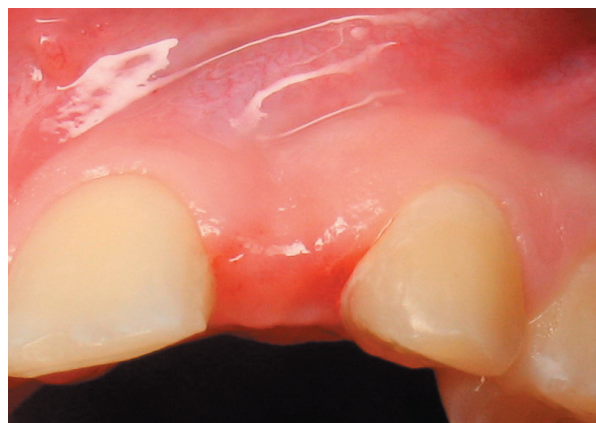Cone beam computed tomography (CBCT) is capable of producing three-dimensional (3D) images that can guide diagnosis, treatment, and follow-up. In addition, CBCT provides 1:1

measurements and eliminates superimposition and geometric distortions.

Conventional medical CT systems offer similar advantages, and also provide information about soft tissue which CBCT does not. However, dental CBCT generates 3D data at a lower cost and with substantially lower absorbed doses of radiation than conventional CT.

In addition, the larger size of conventional CT units makes them poor alternatives for dental offices.

Figure 1.
The clinical appearance of this edentulous site creates the suspicion of a thin alveolar ridge. See Figures 2 and 3 on page 2.



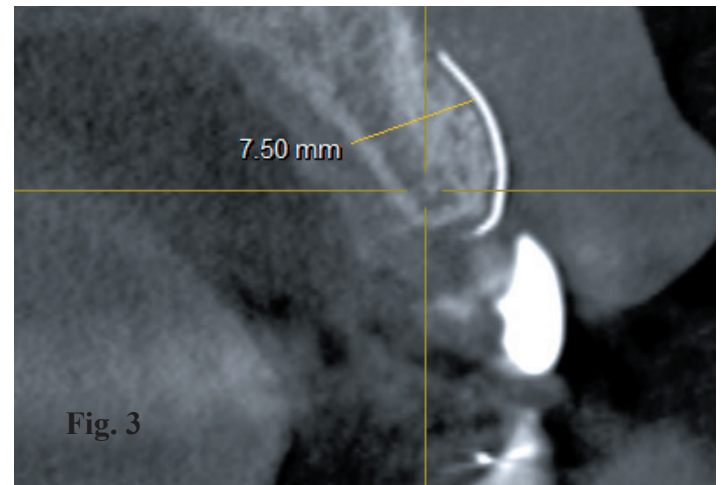
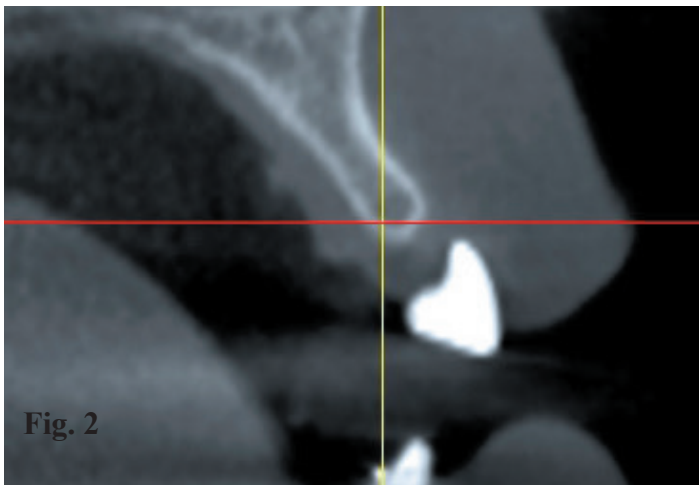


Figure 2. A CBCT scan confirms the thickness of the bone in the buccal-lingual dimension is inadequate for placement of a dental implant. **Figure 3.** Following ridge augmentation, a follow-up CBCT scan shows the bone is now sufficient for placement of an implant.

Applications in Periodontics

The rapidly increasing use of CBCT combined with the use of dedicated dental implant software has revolutionized the planning and placement of dental implants.

CBCT offers a more accurate and safer positioning of dental implants, may reduce the time necessary for implant surgery, and often eliminates the need for open flap surgery. Furthermore, it facilitates a team approach, facilitating a truly restoratively-driven treatment plan.

Dedicated computer software allows visualization and manipulation of the images of the patient's jaw bone and surrounding tissue, making possible the most accurate approach to implant surgery. Without CBCT, clinicians would not be able to perform guided surgery, which facilitates extremely precise implant placement.

Quality images obtained by computerized tomography permit the implant surgeon to determine the height and width of available bone, soft-tissue thicknesses, proximity and root anatomy of adjacent teeth, and other vital structures.

The use of three-dimensional imaging also allows accurate visualization of structures within the antral space. Thickened sinus membranes, mucous retention cysts, septa, lateral wall bony thickness and location of the arterial vessels traversing the lateral wall are not able to be accurately discerned on the traditional two-dimensional periapical radiograph.

This information is critical to performing sinus lifts and may have a significant impact on the results of open sinus lift surgery.

CBCT enables the clinician to choose the correct implant size to position it appropriately in the arch.

CBCT also provides a more accurate measurement of bone defects thus allowing clinicians to assess dehiscence, fenestration defects, and the true dimensions of intraosseous cysts.

Misch et al have observed that 2D radiographs are inadequate for detecting changes in bone levels or determining the architecture of osseous defects. Projection errors in 2D radiography may cause dentists to underestimate the amount of bone loss or available bone, thus leading to errors in identifying anatomical reference points.

Applications in Oral and Maxillofacial Surgery

Because CBCT eliminates the structural superimpositions seen in panoramic images, it allows accurate measurement of surface distances. This particular advantage has made CBCT the technique of choice for investigating, evaluating and managing maxillofacial trauma.

CBCT is widely used in planning orthognathic and facial orthomorphic surgeries. Because advanced CBCT software allows minimum visualization of soft tissue, oral surgeons can control post-treatment esthetics in cases of cleft palate.

CBCT images are also used for:

- Determining bone structure and tooth orientation.
- Assessing impacted or supernumerary teeth and the relationship of these teeth to vital structures.
- Pre- and post-surgical assessment of bone graft recipient sites.
- Evaluation of jaw changes resulting from osteonecrosis.
- Evaluation of paranasal sinus pathology and/or defects.

- Evaluation of patients with obstructive sleep apnea to determine an appropriate surgical approach.
- Locating the origin, location and extent of jaw pathology.
- Detecting, measuring and treating jaw tumors.

Applications in Orthodontics

CBCT is a reliable tool for assessing the proximity of impacted teeth to vital structures that could inhibit orthodontic movement. With new orthodontic assessment software, orthodontists can

use CBCT images for cephalometric analysis, making it the tool of choice for assessing facial growth, age, airway function, and tooth eruption disturbances.

When temporary anchorage devices (TADs) are used to enhance anchorage, CBCT provides visual guides for safe insertion, thus avoiding accidental and perhaps irreparable damage to existing roots.

Applications in TMJ Disorders

Diagnostic imaging of the temporomandibular joint (TMJ) is

crucial for proper diagnosis of joint disease and dysfunction.

CBCT makes it possible to examine the joint space and the true position of the condyle within the fossa, which is instrumental in revealing possible alterations in the position of the joint disk.

CBCT's accuracy and elimination of superimposition makes it possible to measure the roof of the glenoid fossa and visualize the location of the soft tissue around the TMJ, which can reduce the need for MRI.

CBCT is the best imaging device for cases involving trauma, fibrous ankylosis, pain and condylar cortical erosion and cysts.

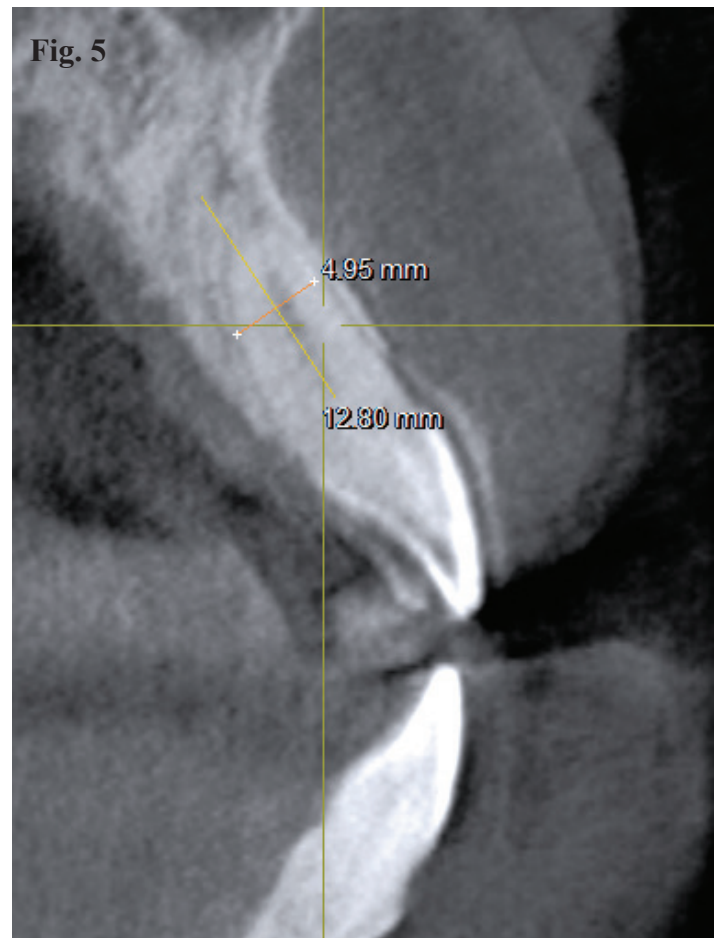
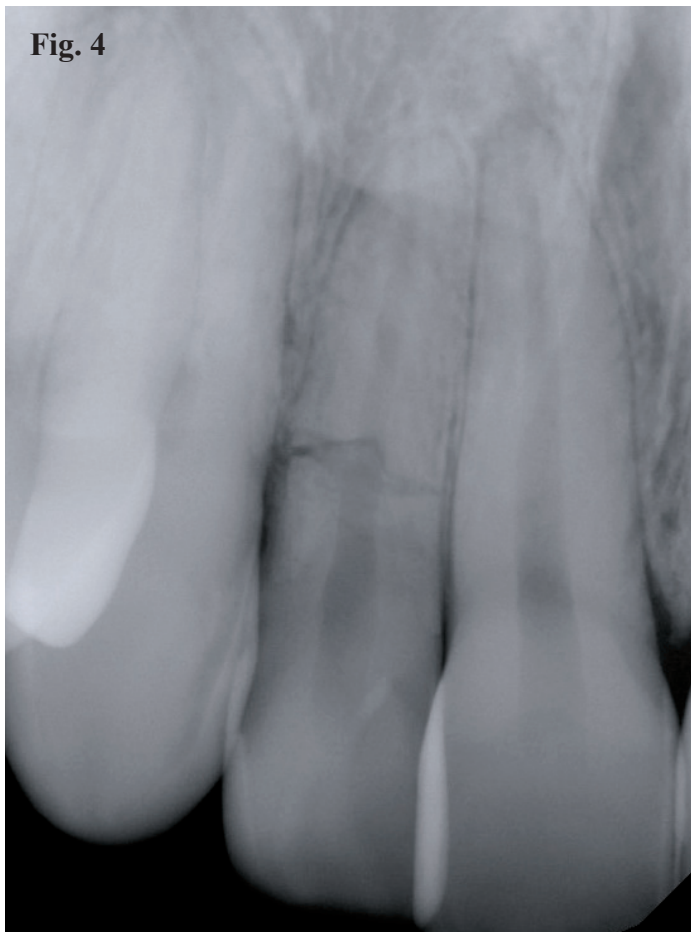


Figure 4. A periapical radiograph reveals a horizontal fracture on the upper right lateral incisor at the level of the crestal bone. **Figure 5.** A CBCT scan of the fractured tooth reveals good buccal and lingual plates, which would allow a plan for immediate implant placement.

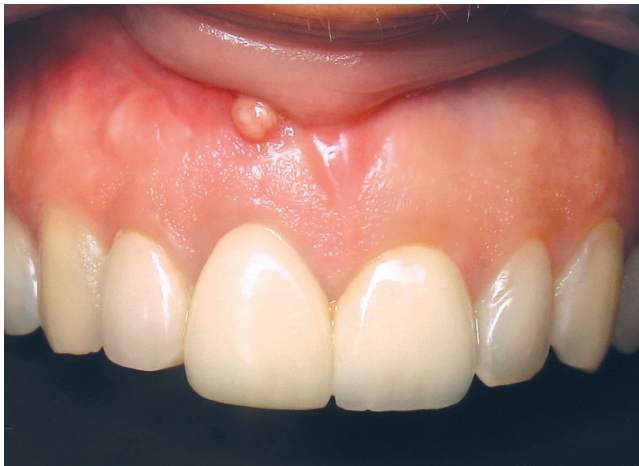

Figure 6.
This patient presented with a draining fistula on the labia of tooth #8.

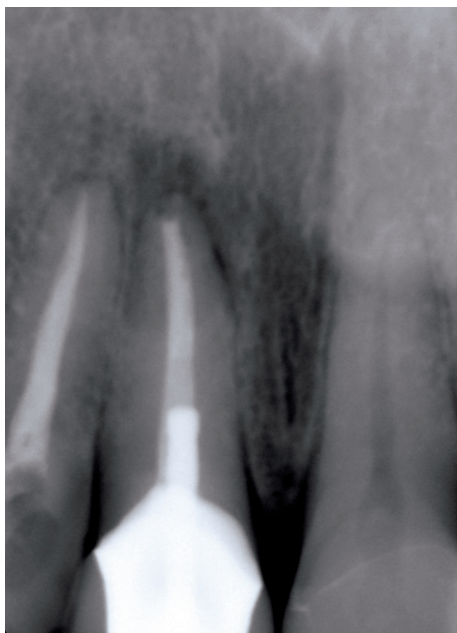

Figure 7.
A periapical radiograph shows prior endodontic treatment, and suggests the possibility an immediate dental implant could be placed.

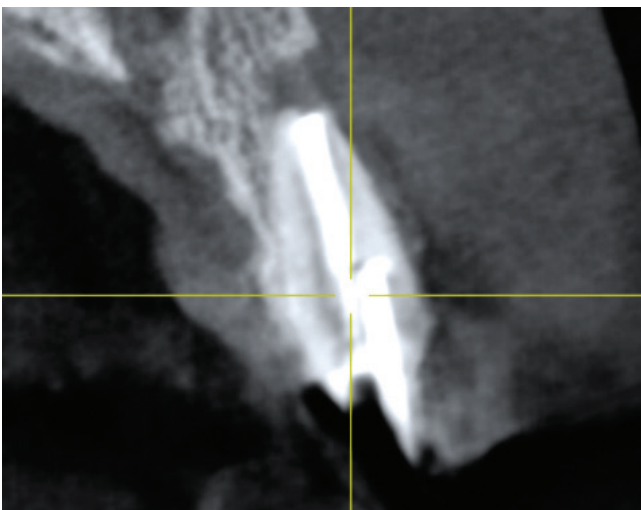

Figure 8. *A CBCT scan rules out the placement of an immediate implant due to a very deficient buccal plate, and significant bone loss in the sinus tract area.*

Applications in Endodontics

CBCT imaging is useful for detecting, diagnosing and determining the appropriate treatment for many endodontic conditions.

While controversial, several studies have suggested that in diagnosing periapical lesions, CBCT images can be used to differentiate between apical granulomas and apical cysts.

CBCT is often a reliable and far more accurate tool than 2D imaging to:

- Detect external, internal and cervical root resorption and the extent of a lesion.
- Determine the number and morphology of roots and associated canals, both main and accessory, establish working lengths, and determine the type and degree of root angulation.
- Determine pulpal extensions and the position and location of fractured instruments.
- Assess a tooth's proximity to adjacent vital structures, which allows for accurate measurement of the size and extent of a lesion and the anatomy of the area.
- Detect vertical root fractures, measure the depth of dentin fracture, and detect horizontal root fractures.
- Detect inflammatory root resorption, a diagnosis that is rarely possible when using conventional 2D radiographs.

Conclusion

CBCT scanning represents a significant advancement in dental and maxillofacial imaging and offers numerous advantages over 2D radiography.

