

From Our Office to Yours...

Reconstruction of a deficient alveolar ridge is generally required as the consequence of alveolar bone loss from post-extraction resorption, periodontal bone loss or trauma.

Resorption can occur as horizontal loss with a narrowing of the alveolar ridge or vertical bone loss resulting in a shortened distance to the floor of the maxillary sinus or mandibular neurovascular bundle. Such bone loss may have a significant impact on esthetic outcomes.

This issue of **The PerioDontaLetter** will discuss the factors responsible for alveolar ridge deficiencies, methods to minimize resorptive changes and numerous techniques to reconstruct deficient ridge anatomy.

As always, we welcome your comments and suggestions.

Guided Lateral Ridge Augmentation

Post-extraction bone resorption is often unavoidable with the majority of resorptive changes occurring within six months of the extraction. These changes can result in a dimensional reduction of as much as 40-60% of ridge height and width.

Bone loss generally occurs on the facial and buccal aspect of ridges with minimal changes noted on the palatal and lingual surfaces. Kan et al reported that bone is frequently thin over roots in the anterior region. Consequently this area is vulnerable to

ridge resorption more than 80 percent of the time.

Because of thin bone in this area, both maxillary and mandibular anterior teeth are associated with alveolar fenestration or dehiscence which also contributes to the loss of facial plate following extraction. Consequently extraction of anterior teeth may result in the removal of the thin facial plate.

Untreated periodontitis results in vertical and horizontal patterns of bone loss. Progressive bone loss can accelerate and magnify the ridge

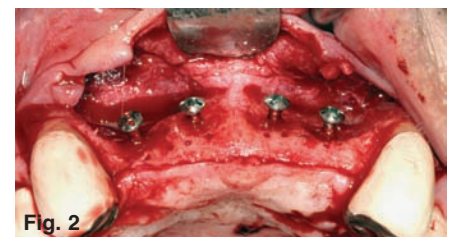
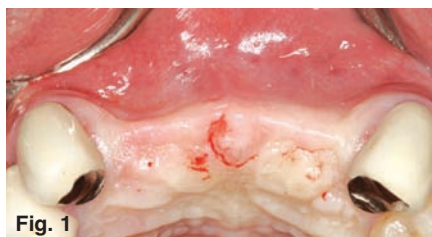

Figure 1. The preoperative clinical appearance of the alveolar ridge reveals a significant facial concavity. Figure 2. Flap reflection confirms the presence of a significant facial concavity. Tenting screws were placed and a hard tissue grafting material was utilized and covered with a barrier membrane to augment the area. (See Figures 3 and 4 on page 2.)

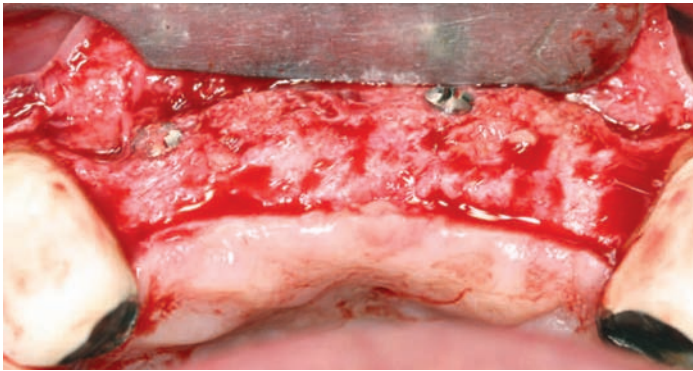


Figure 3. Following six months of wound healing, flap reflection reveals tremendous new bone growth.

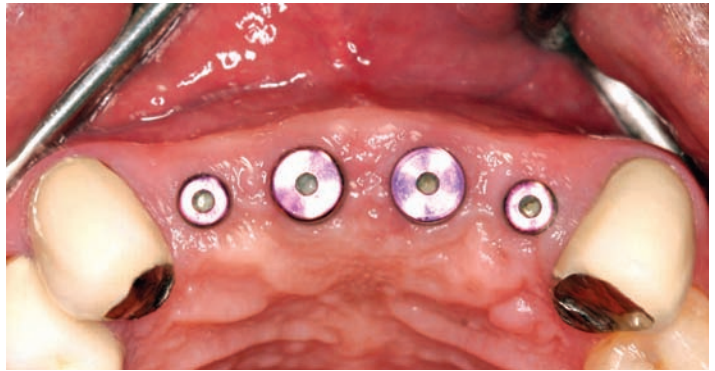


Figure 4. Ridge augmentation permitted implants to be placed in an ideal position for esthetics and function.

deformities which occur following removal of these teeth.

Vertical root fracture associated with past endodontic therapy and post placement as well as unresolved apical infection and endodontic surgery are also conditions that can result in loss of alveolar bone prior to the extraction of the compromised tooth.

Multiple adjacent extractions, tobacco use, diabetes and excessive pressure from removable prostheses all compromise bone healing and contribute to alveolar bone loss.

Methods to minimize alveolar bone loss include:

- Phase extraction of multiple adjacent teeth
- Sectioning of multi-rooted teeth
- Bone grafting at the time of extraction

- Implant placement at the time of extraction
- Orthodontic extrusion to coronally reposition the bone
- Flapless extraction technique

Reconstruction of the Deficient Ridge

A variety of techniques, regenerative materials and barriers have been successfully used to reconstruct deficient ridges.

Most often ridge augmentation is a preliminary phase prior to placement of dental implants.

Reconstruction of the deficient soft tissue may also be beneficial to regenerate the ridge to facilitate the placement of pontics in fixed prosthodontics.

Following are some of the most common techniques of ridge augmentation.

Lateral Ridge Augmentation

Lateral ridge augmentation methods include particulate bone grafts and monocortical block grafts.

Guided bone regeneration (GBR) using barrier membranes is an alternative technique to reconstruct all types of alveolar bone defects.

Ridge splitting and expansion are also well documented for treating horizontal bone deficiencies.

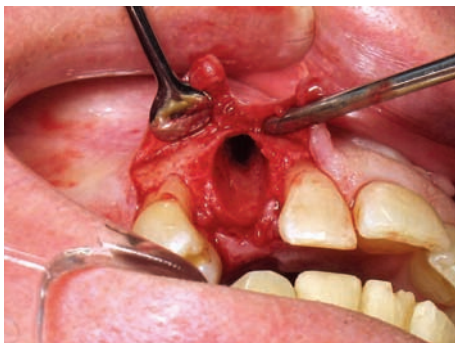

Figure 5. A fractured maxillary right canine was extracted.

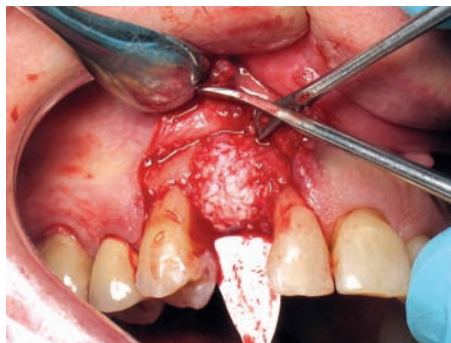

Figure 6. A particulate bone graft was used to fill the socket.

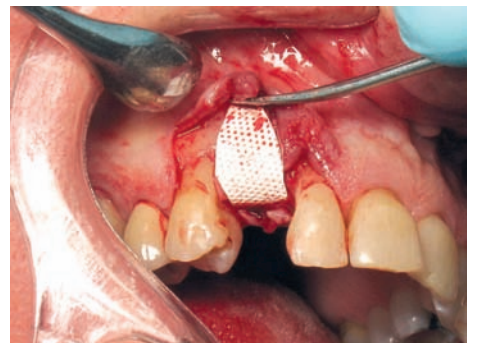

Figure 7. A barrier membrane was placed to retain the bone graft and exclude connective tissue ingrowth.

Particulate Bone Grafts

Autologous particulate bone grafts can be harvested from any edentulous jaw site either in smaller particle sizes or in large block size.

The most commonly used materials for allograft particulate bone grafting are Demineralized Freeze-Dried Bone Allograft (DFDBA), Freeze-Dried Bone Allograft (FDBA), and Deproteinized Bovine Bone Mineral (DBBM).

Particulate bone grafts have the advantages of encouraging:

- More rapid ingrowth of blood vessels (revascularization)
- Greater surface area for osteoconduction
- Enhanced exposure to osteoinductive growth factors
- Better bone remodeling compared with monocortical bone grafts.

Monocortical Block Grafts

Horizontal alveolar deficiencies can also be reconstructed with a monocortical block bone grafts.

A block of bone is harvested from a remote site to increase the width of bone. The block may be harvested from the mandibular symphysis, iliac crest or tibia and subsequently fixated to the deficient ridge with bone screws.

Autogenous block grafts from the mandibular symphysis or ramus are advantageous in that they can be procured in an outpatient procedure.

Block grafts exhibit a low rate of resorption and better revascularization than particulate grafts.

Block grafts from intraoral or extra-oral sources have the advantage of allowing reentry slightly sooner for implant placement.

Common post-operative problems include parasthesia, excessive bleeding at the donor site, permanent defects at the harvest site and other untoward results.

Block allografts have substantially reduced these morbidities.

Use of Barriers in Addition to Particulate Bone Grafting

If a bone defect does not have sufficient osseous walls to contain the graft and if an implant is to be placed simultaneously, guided bone regeneration (GBR) is indicated to produce a stable environment and support bone formation. Success rates for the GBR procedure are similar to that of block grafts.

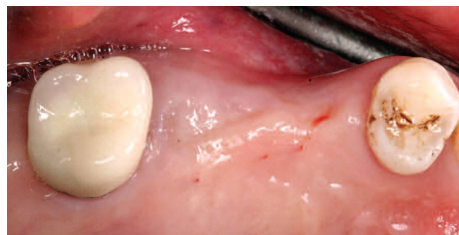

Figure 8. A preoperative photograph reveals an obvious buccal concavity in the alveolar ridge.

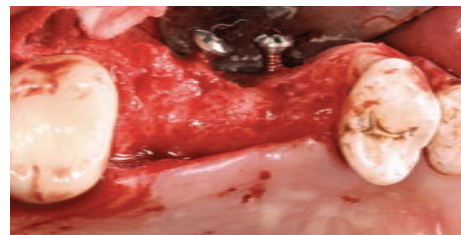

Figure 9. Following flap reflection tenting screws were placed in the concavity prior to bone grafting.

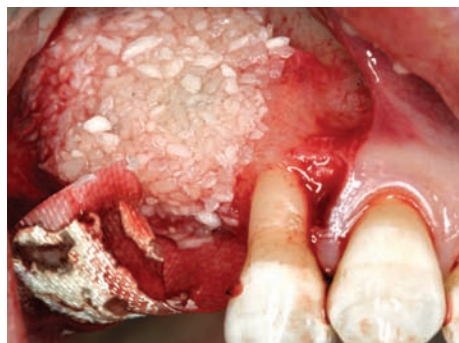

Figure 10. The concavity was filled with mineralized freeze-dried allograft and a barrier membrane was used to cover the graft.

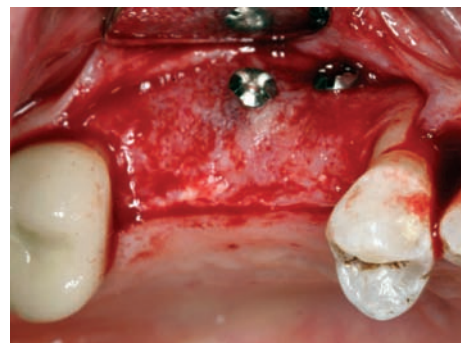

Figure 11. Flap reflection six months after grafting reveals successful augmentation which completely filled the alveolar defect.

Toscano et al found lateral ridge augmentation produced an average gain in ridge width of 3.5mm. The use of additional biologic modifiers have improved the outcome for bone augmentation procedures.

Soft Tissue Management for Lateral Ridge Augmentation

Management of existing soft tissue including increasing the quantity and quality of soft tissue can be beneficial to producing esthetic restorative outcomes.

Flap design, reflection and manipulation should be designed to optimize blood supply and wound closure.

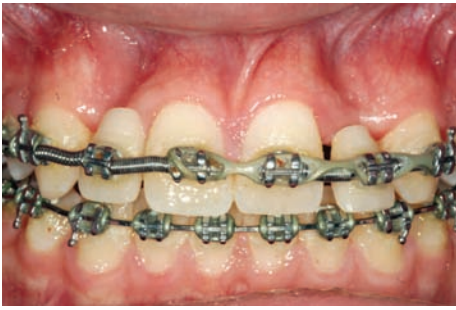

Figure 12. This patient approached orthodontic completion with obvious alveolar concavities

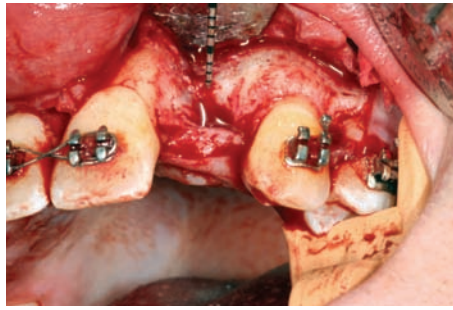


Figure 13. The severity of the concavity was revealed on flap reflection.

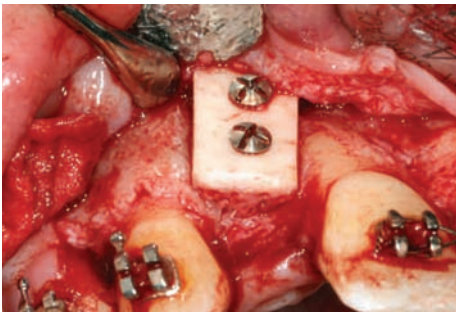


Figure 14. A block bone graft was placed and retained with two fixation screws.

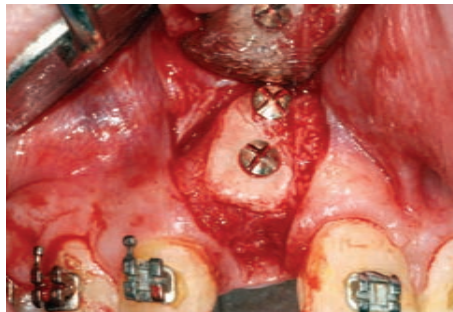


Figure 15. Following seven months of healing, the graft procedure completely filled the concavity at the time of implant placement.

The design and management of mucoperiosteal flaps must consider the increased dimensions of the ridge after augmentation as well as esthetic outcomes.

The surgical procedure must be executed with utmost care to preserve the maximum vascularity to the flap and to minimize tissue injury.

It is also suggested that no removable prosthesis be inserted for at least six weeks after surgery to avoid pressure over the wound during the early healing period.

If possible, selection of a tooth supported interim provisional is recommended to eliminate pressure on the healing bone graft. This is a critical

element of the prosthodontic support the restorative colleague provides in the reconstruction of ridge deformities.

Conclusion

Successful lateral ridge augmentation with bone grafting makes it possible to place a dental implant in an area which previously had an inadequate amount of bone.

Predictable outcomes of these procedures depend on an adequate blood supply, maintenance of a stable, protected space and flap management, permitting tension-free flap closure as well as avoidance of pressure on the graft site from an interim prosthesis.

In 1981, Dr. William Ammons, an esteemed periodontal educator wrote: "The future of ridge augmentation lies in the prevention of the ridge defect at the time of the extraction rather than reconstruction of the resorbed ridge."

Carefully coordinated extraction and grafting procedures can minimize the need for extensive reconstruction in the future.

Consultations with your periodontist PRIOR to extraction may be the single most important determinant for producing a functional and cosmetically acceptable implant supported restoration.



"The future of ridge augmentation lies in the prevention of the ridge defect at the time of the extraction rather than reconstruction of the resorbed ridge."

Dr. William Ammons