

From Our Office to Yours...

Failure to address inadequate bone volume may result in successful implant integration but a prosthetic and esthetic nightmare.

Alveolar ridge preservation and socket preservation prevents bone resorption, conserves bone volume, maintains soft tissue contours and permits implant placement in the most favorable restorative position.

*This current issue of **The PerioDontaLetter** will discuss the socket grafting procedures currently available to treat various post extraction alveolar ridge defects.*

As always, we welcome your comments and suggestions.

Socket Grafting for Esthetically Favorable Implant Position

Preserving the dimensions of the alveolar ridge for implant placement is esthetically important to ensure a scalloped gingival margin, bilaterally symmetrical gingival height, intact interdental papillae, naturally-occurring root convexities and natural tooth proportions.

It is also important in the preservation of posterior ridge height inferior to the floor of the sinus and superior to the mandibular neurovascular bundle.

It is far better to address potential alveolar ridge defects before the tooth is extracted than after. Two-thirds of bone resorption occurs within the first few months following tooth extraction.

Within a year, half of the alveolar ridge may be lost subsequent to the loss of a tooth.

Careful extraction of the tooth and regeneration of the socket can prevent ridge collapse, preserve gingival and papillary tissue and reduce the number of procedures required to correct the ridge defect if one should occur.

A well-planned extraction with socket walls intact will result in less bone loss if the socket graft is placed at the time the tooth is removed. It is axiomatic that thin biotypes are subject to more bone loss than those with thick biotypes.

When one or more walls of the socket are missing, the healing potential of

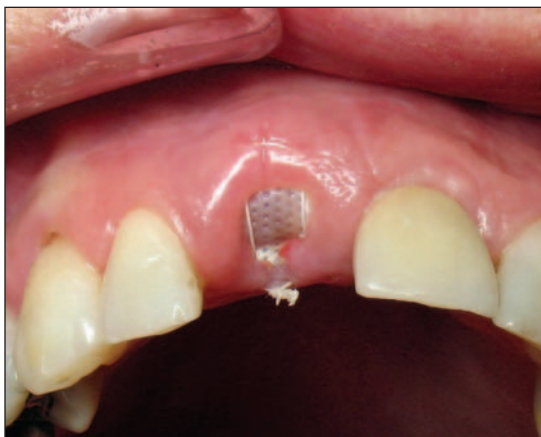

Figure 1. Two weeks following tooth removal, socket bone grafting and barrier placement, the soft tissue response and presence of arch width is visible.

the socket is compromised and socket grafting is indicated. This may involve the use of a barrier membrane to aid in rebuilding the alveolar wall.

Factors Favoring Bone Regeneration

Atraumatic extractions provide an enhanced environment for bone regeneration. Some of the reasons are:

1. The extraction process sets up a regional acceleratory phenomenon which increases the rate of repair and provides bone morphogenic protein to the site.
2. Maintenance of bony socket walls protects the graft from micromovement.
3. Extraction and other "injury" to the bone results in the production of growth factors which enhance healing and regeneration.
4. The maintenance of space is critical for regeneration. The preservation of socket walls creates a natural and protected space.
5. Maintaining as many socket walls as possible provides enhanced vascularity and stimulates healing.

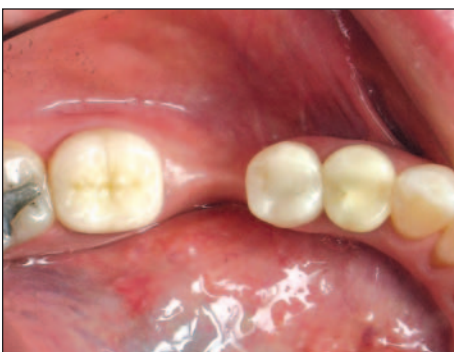

Figure 2. Severe alveolar ridge collapse has occurred one year following extraction. This likely could have been prevented with socket grafting at the time of tooth removal.

Socket Grafting Procedures

Even with socket grafting, buccal bone resorption still occurs in many extraction sockets. However, when new bone formation is stimulated in the area of resorption, the net result is greater bone volume.

Four basic socket grafting procedures have proved effective in controlled clinical trials.

1. Guided Bone Regeneration
2. Bone Grafting
3. Guided Bone Regeneration Plus Bone Grafting -- the most popular technique today
4. Biological Agents

Misch et al studied different graft materials and techniques based on the number of bony walls that remained after the tooth is removed. They found:

- A thick five bony wall defect will grow bone with almost any resorbable graft material, for example, an alloplast, allograft or autograft. It is not absolutely essential to graft these sockets, which are likely to fill naturally. However, the addition of a graft will permit earlier implant placement.
- Four bony wall defects -- when a wall of bone is thinner than 1.5mm or a labial plate is missing -- require an autograft or an alloplast such as freeze-dried bone or an alloplast (synthetic material) with barrier membrane and guided bone regeneration to increase the predictability of restoring the original bony contour.
- A two to three bony wall defect requires a resorbable graft material and, at least, some autogenous bone with a barrier membrane, and frequently require a secondary ridge augmentation procedure.

- A one wall bony defect is most predictably treated with a cortical autograft (block graft) fixated to the host bone following soft tissue healing.

Guided Bone Regeneration

In sockets with up to 5mm of vertical buccal bone loss, an absorbable or non-absorbable membrane can be adapted against the inner aspect of the buccal wall and over the socket opening.

In sockets with more than 5mm of vertical buccal bone loss, an absorbable or non-absorbable membrane can be adapted against the outer aspect of the buccal wall and over the socket opening.

Although an effective barrier effect is provided by e-PTFE membranes, they are prone to exposure (dehiscence) to the oral cavity making primary closure of the wound mandatory. Because of this, along with the need to tack down the membrane and remove it later, this approach is not routinely used to rebuild sockets today.

Bone Grafting

Wound healing studies show that ungrafted sockets lose an average of 17 percent of horizontal dimension and 25 percent of vertical dimension. With socket grafting, the horizontal bone grew an

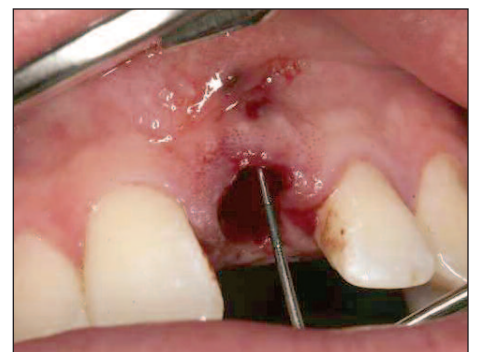

Figure 3. At the time of extraction, a fenestration in the buccal plate was found with a periodontal probe. (See Figures 4, 5 and 6 on page 3.)

average of one percent and vertical bone loss was reduced to an average of eight percent.

While both bioactive glass and bovine-produced bone mineral stimulate native bone formation, remnants of the graft material usually remain. Their role in long-term osseointegration is poorly understood and they may delay socket healing. As of now, these materials are probably not the best choice.

In choosing a bone graft material, the clinician must consider how much native bone/implant contact is necessary for sustained osseointegration.

Guided Bone Regeneration with Bone Grafting

Grafting of sockets seems to be more beneficial than not. Studies of grafted sockets showed that average horizontal bone loss was 19% (1.7mm) less than in ungrafted sockets. Vertical bone gained an average of .3mm compared to a loss of 2.3mm in ungrafted sockets.

Misch found grafting using a barrier membrane with a mineralized alloplast/freeze-dried bone or a modified socket seal surgery effective in treating a four to five wall bony socket. When the socket plate is thin, the socket may be filled with freeze-dried bone or mineralized hydroxyapatite.

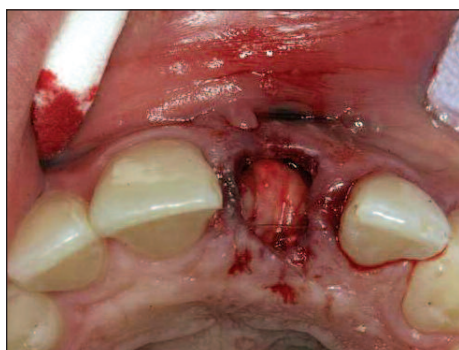

Figure 4. A bone graft and barrier membrane were placed at the time of extraction.

The tuberosity offers a variable amount of trabecular bone and may be a good source of autologous graft material. The cancellous nature of the bone allows it to be molded into an alveolar defect such as an extraction socket.

The tuberosity autograft has growth factors for osteoinduction and to accelerate blood vessel growth in the host site making it an excellent donor source for bone regeneration.

The disadvantage to this procedure is the need for a second surgical site and the lack of access in many patients to harvest tuberosity tissue.

Biological Agents

Studies of sockets treated with recombinant bone morphogenic protein showed an average gain of 2.7mm more horizontally and an average loss of less than 1.15mm vertically than in untreated sockets.

Almost all of the data is on socket treatment of anterior teeth and bicusps and usually in combination with a bone graft. Data on extraction sockets of multi-rooted teeth is almost non-existent.

Conclusion

The clinician's goal should always be to perform minimally traumatic extraction and complete removal of granulomatous tissue so bone can regenerate naturally.

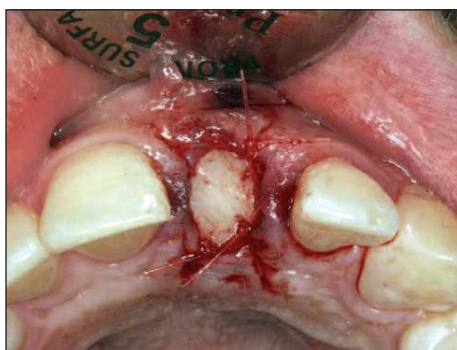


Figure 5. A gingival graft was sized and placed to cover the barrier membrane.

Beyond that, the ultimate goal is to do everything clinically possible to promote bone formation in the socket and minimize bone resorption.

Studies show the average implant survival rate with socket grafting is 93.4 percent, close to the survival rate of implants in native bone.

The choice of materials and techniques is dependent upon achieving the ideal environment for bone regeneration, including space maintenance, protection of blood vessels, clot formation, graft stabilization and exclusion of fibrous tissue in the graft.

When possible, prior to the removal of any teeth, consideration should be given to the treatment plan for the replacement of those teeth.

If implants may be an option, socket preservation bone grafts should be considered to maintain the quality of the site for implant placement and the desired esthetic outcome.

Excellent collaborative accountability is very important for the periodontist and the restorative dentist.

We must be very deliberate in enhancing the communication between dental colleagues.

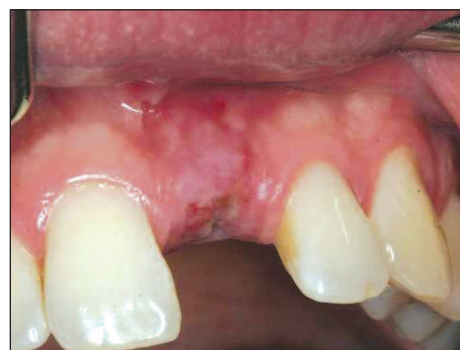

Figure 6. Two weeks following extraction, the soft tissue was almost totally healed.

Periodontal Therapy for the Diabetic Patient

Prevention, early diagnosis and consequent treatment of periodontal disease may have a major impact on the control of diabetes. Research suggests that not only does diabetes influence the progress of periodontal disease, but active periodontal disease also influences the diabetic state.

The systemic inflammatory response generated by inflamed periodontal tissue aggravates insulin resistance and increases blood sugar, thus creating a vicious cycle of diabetes and periodontitis exacerbating each other and putting diabetic patients at increased risk for diabetic complications.

People with diabetes are more than twice as likely to have periodontal disease than people without diabetes because diabetics are more susceptible to contracting infections.

This may be due to numerous physiological phenomena seen in diabetes, such as impaired immune resistance, vascular changes, altered microflora, and abnormal collagen metabolism.

People with uncontrolled diabetes are especially at risk.

A study in the *Journal of Periodontology* found that poorly controlled type 2 diabetic patients are more likely to develop periodontal disease than well-controlled diabetics.

Aggressive management of oral health in diabetic patients may diminish the adverse inflammatory effects on diabetes control.

Several studies have reported that when periodontal infections were treated, the management of diabetes markedly improved.

These studies suggest that the reduction of periodontal inflammation can be very helpful in controlling blood glycemic levels and reducing insulin requirements.

For diabetics, periodontal disease therapy is a long-term venture, requiring some modifications of the customary periodontal treatment applied to non-diabetics.

Diagnosing Diabetes

Through observation of our patients' soft tissue response to periodontal therapy, dentists are in an ideal position to detect alterations which may result in an earlier diagnosis of diabetes.

In addition to the basic diagnostic tools for periodontitis, analysis of subgingival bacteria is another important diagnostic tool for the extended management of periodontal disease in diabetics. Subgingival cultures are frequently helpful in identifying these pathogens.

Recognizing other unexpected soft tissue treatment response patterns may also lead to the discovery of diabetes, including dry mouth, and sporadic, aching pain in the lower anterior teeth without apparent cause.

It is best to treat controlled, insulin-dependent diabetic patients about 90 minutes after a meal and insulin dose.

Ordinarily, this would be midmorning to allow blood sugar levels to drop and to reduce the risk of diabetic complications during treatment. In addition to an appropriate postoperative diet, diabetic

patients usually require antibiotics concomitant with treatment due to their lowered resistance to infection.

The diabetic patient requires close monitoring with shorter maintenance intervals. Because glucose concentrations in diabetics are elevated in gingival fluid and saliva, the diabetic patient with root exposure has a substantially increased incidence of root caries. Fluoride rinses, gels or NaF varnishes may be helpful.

Initiating periodontal care for the diabetic patient should be a foremost concern of physicians as it may make their task easier and reduce insulin requirements.

A close cooperation between the endocrinologist and the periodontist is vital to manage the patient's periodontal problems and diminish the detrimental effects of inflammatory disease on diabetes control and cardiovascular health.

Working in concert, these two disciplines have a greater success in the diagnosis and control of diabetes and periodontitis.



“Aggressive management of oral health in diabetic patients may diminish the adverse inflammatory effects on diabetes control.

Several studies have reported that when periodontal infections were treated, the management of diabetes markedly improved.”